

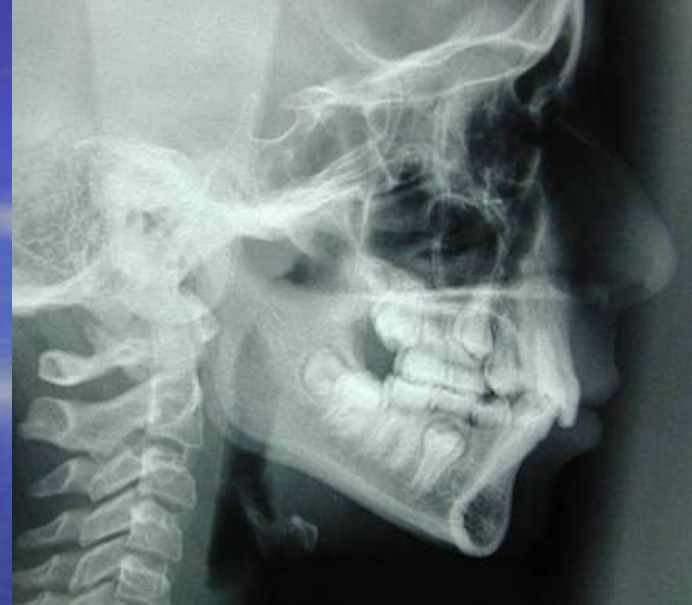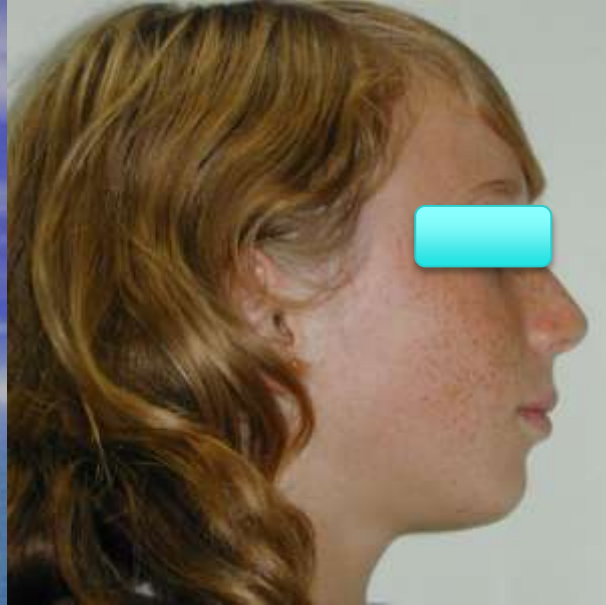



Classe II division 2

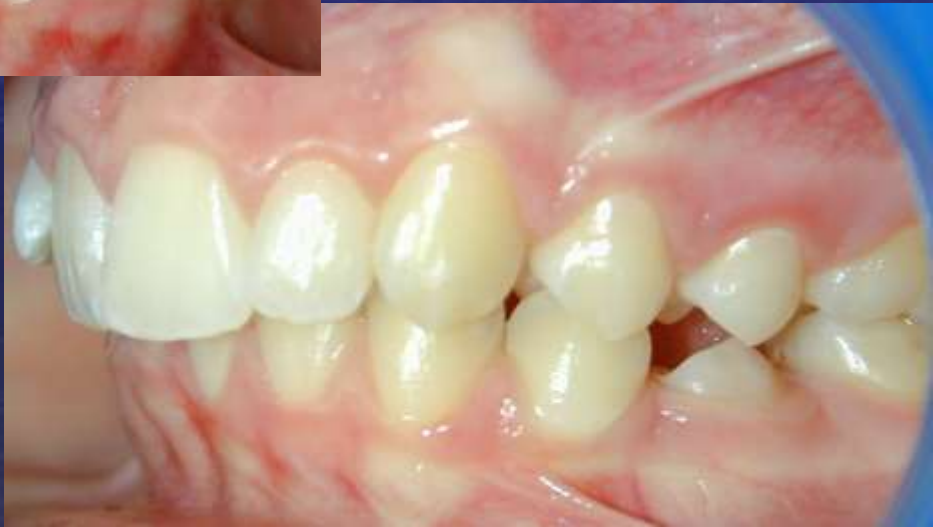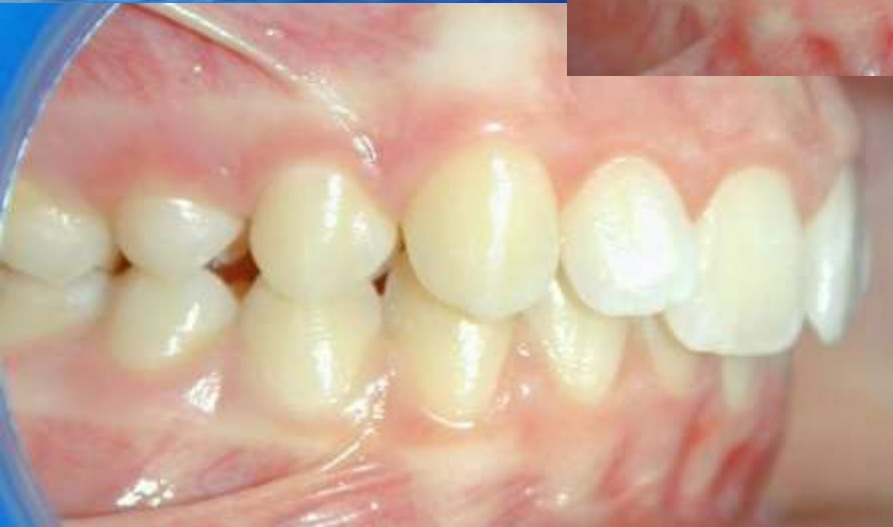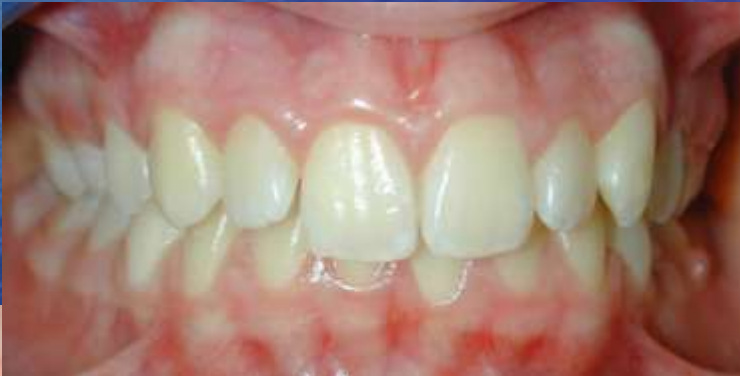Class II division 2

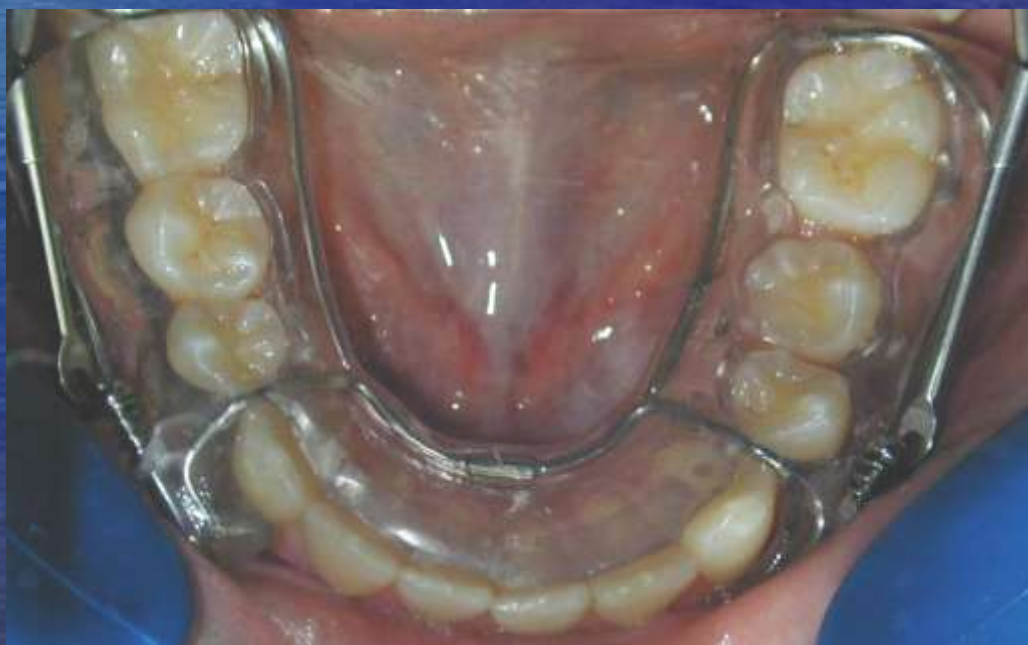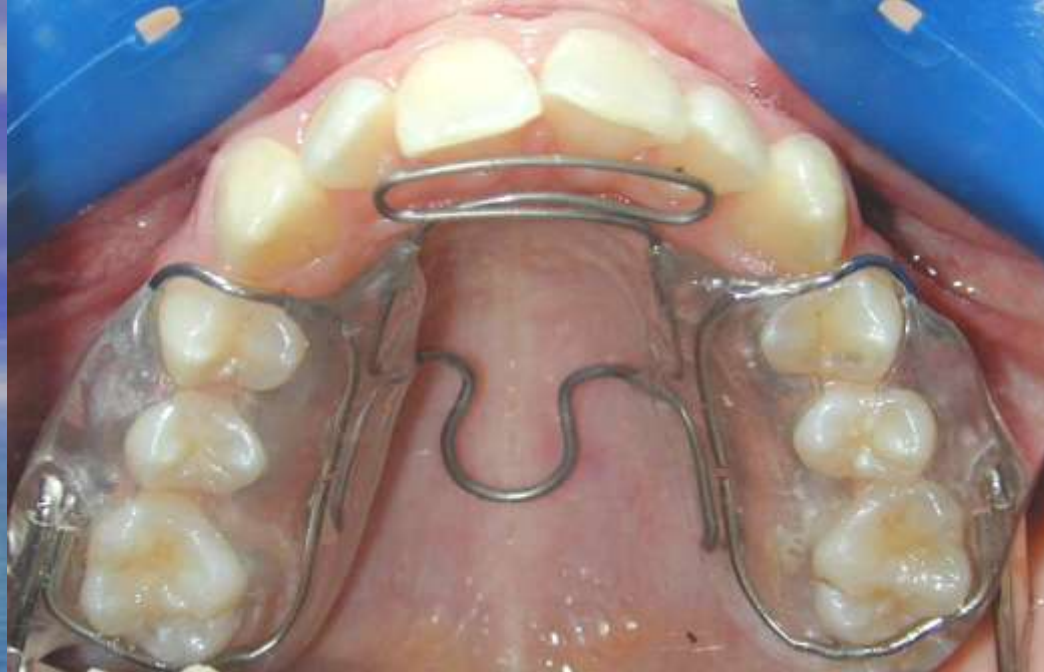Classe II 2 denture définitive ado

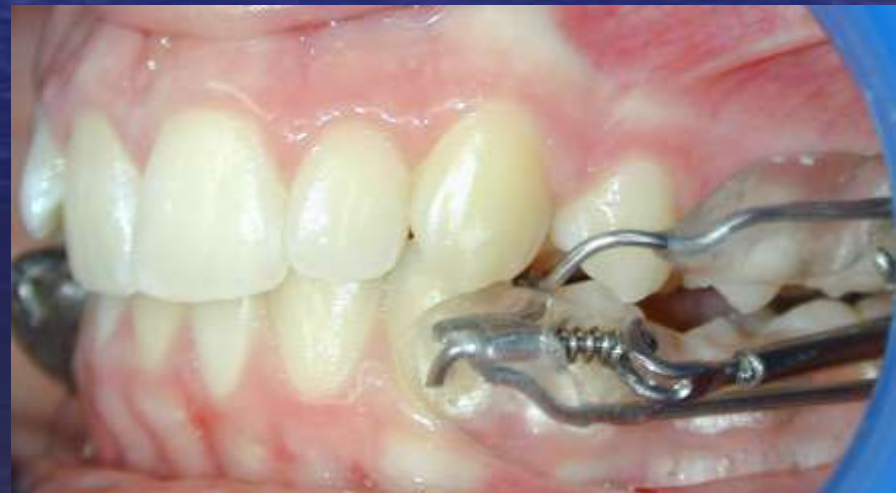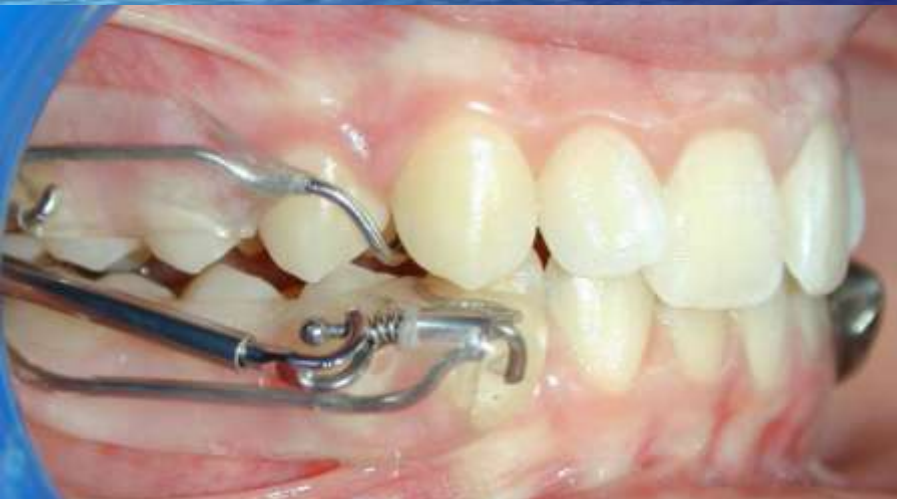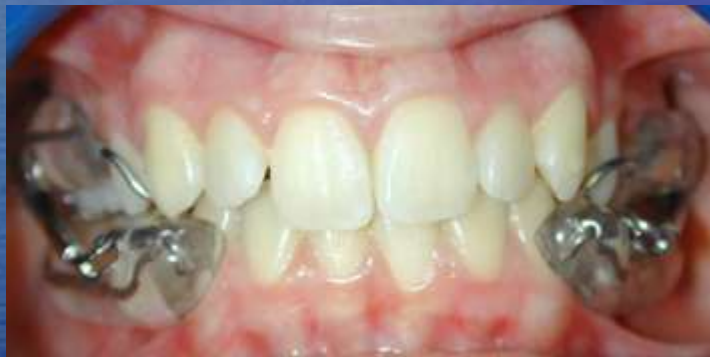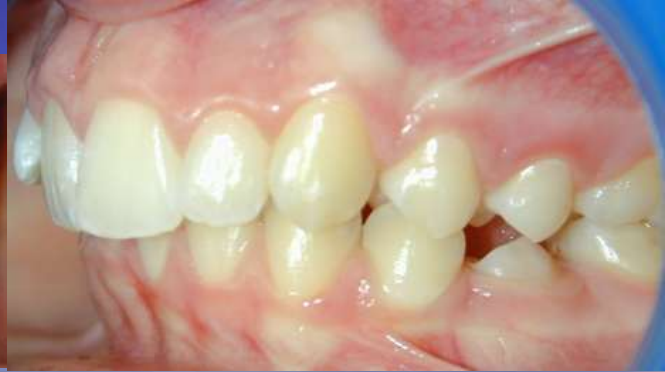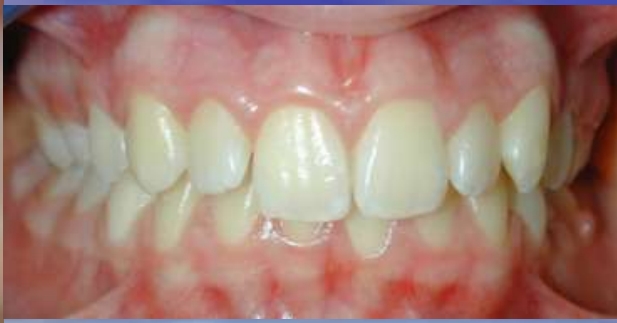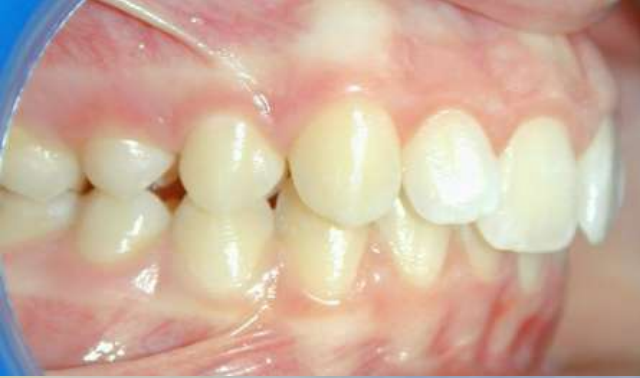Class II division 2 Permanent dentition



L.
13 ans

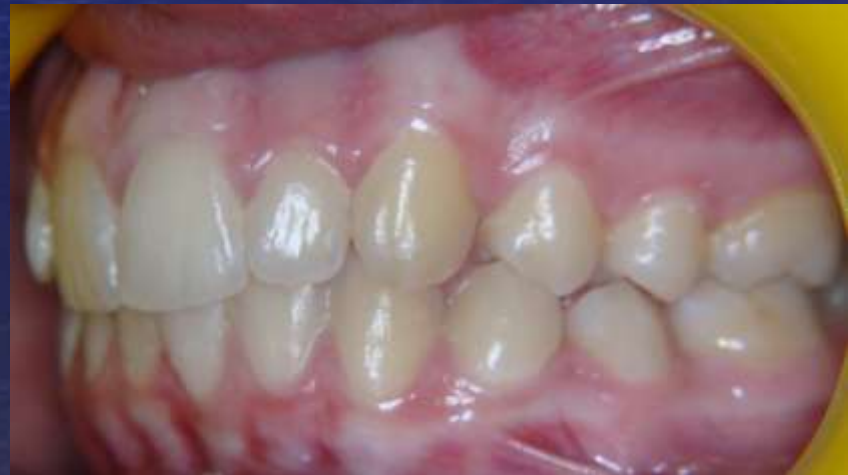
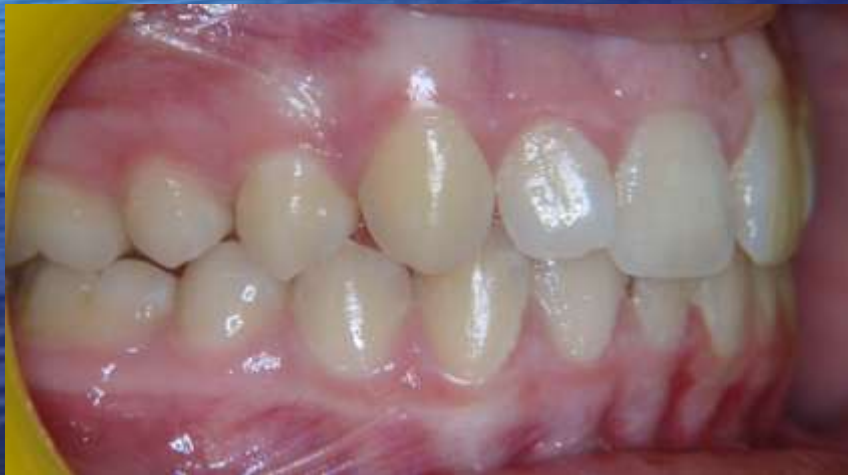
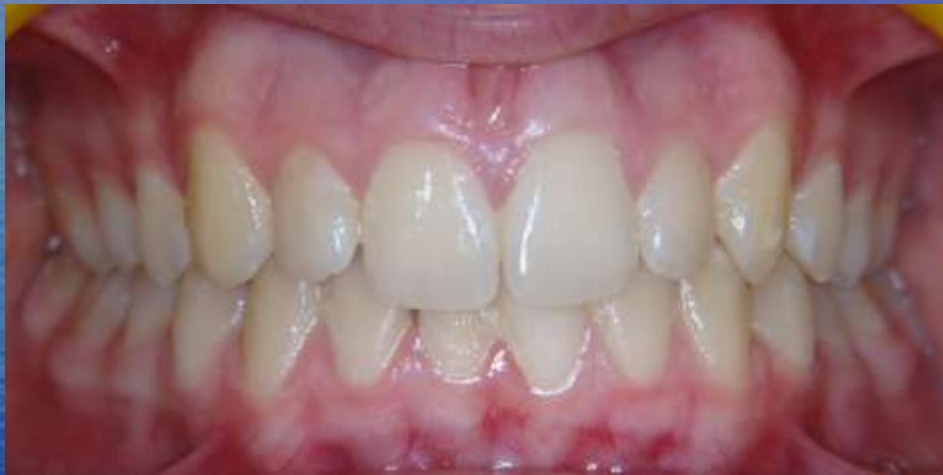


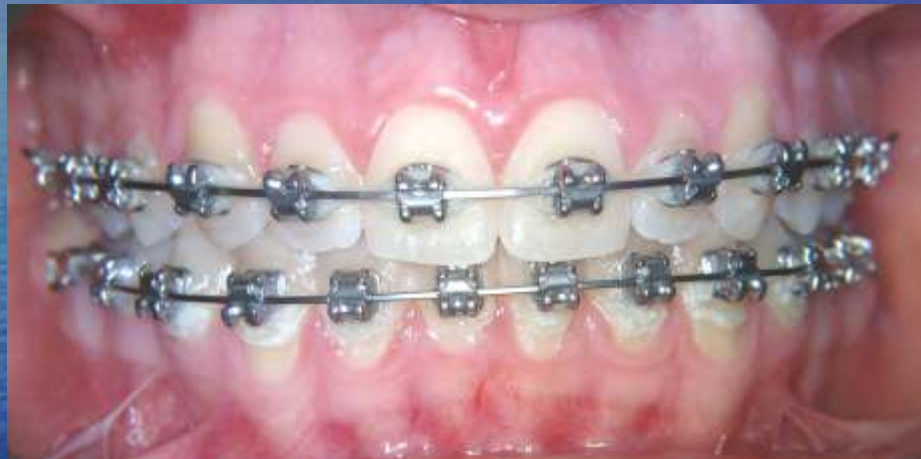


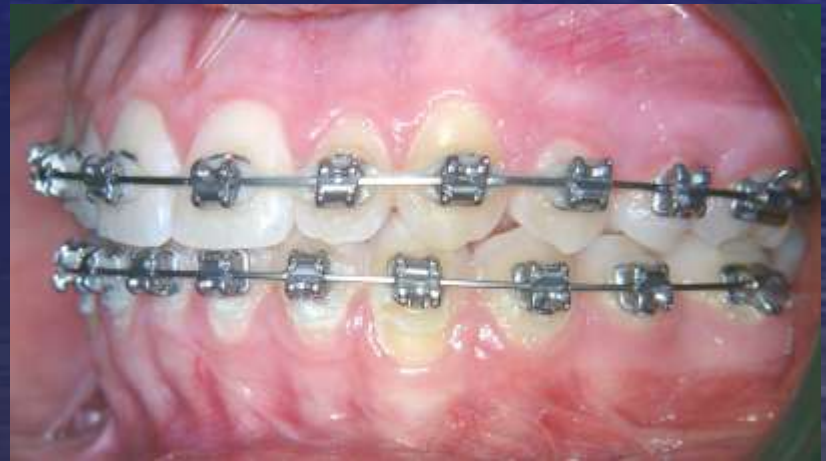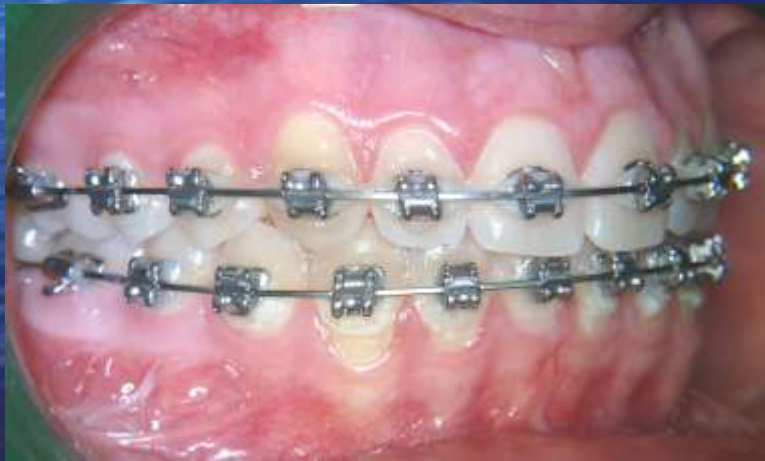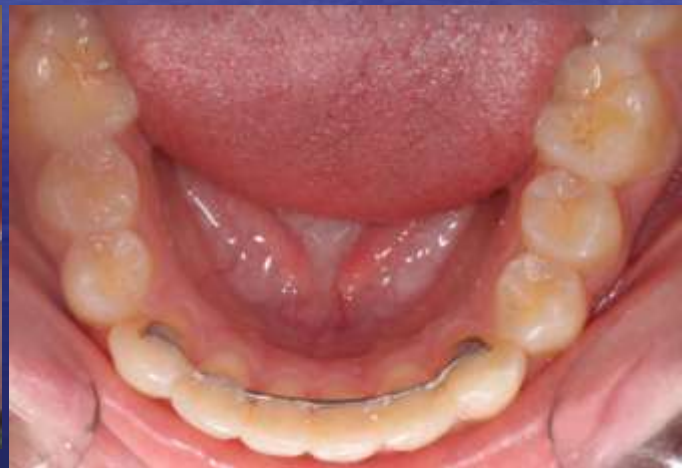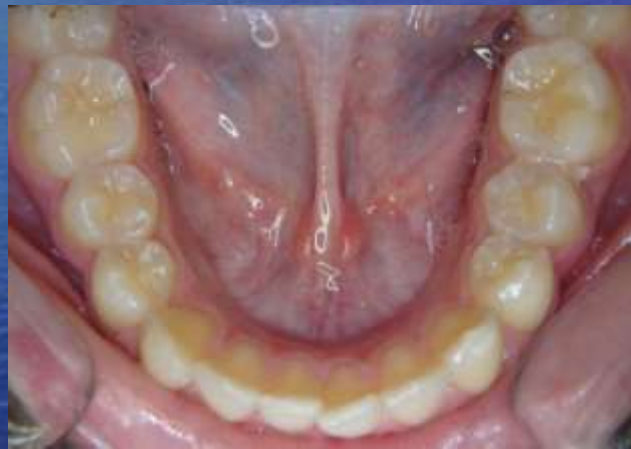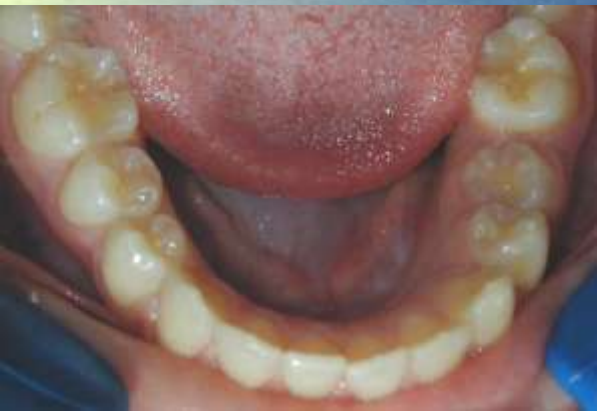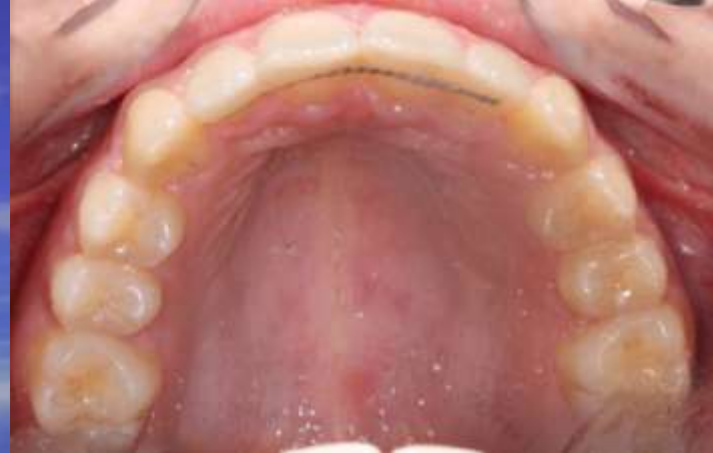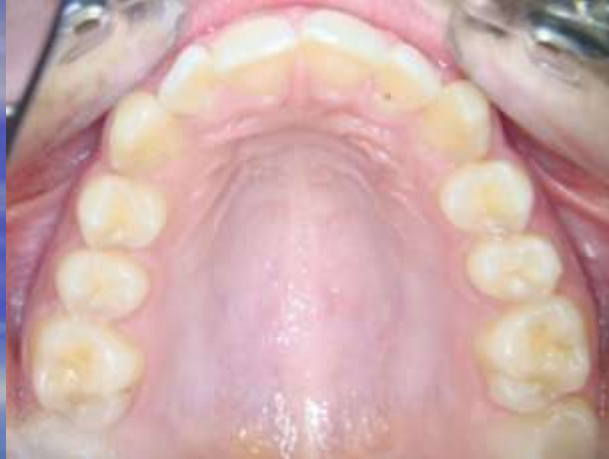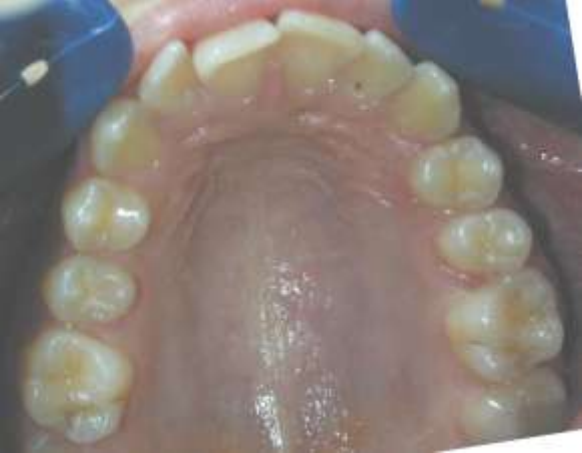PUL + 10 M

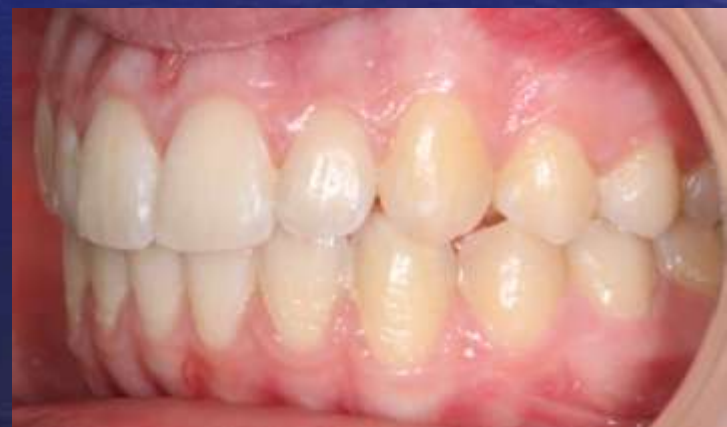
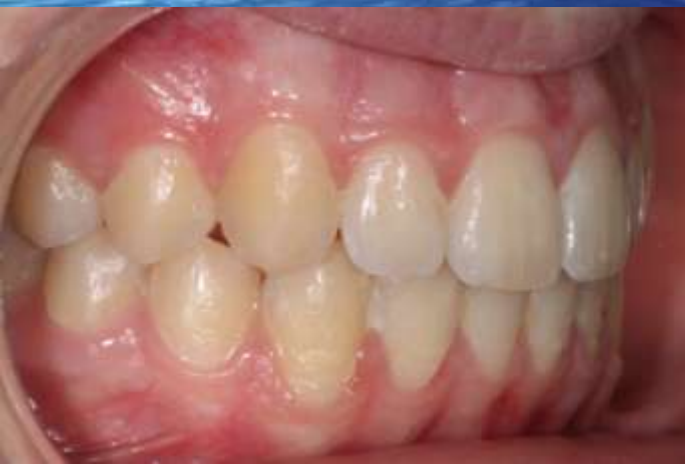
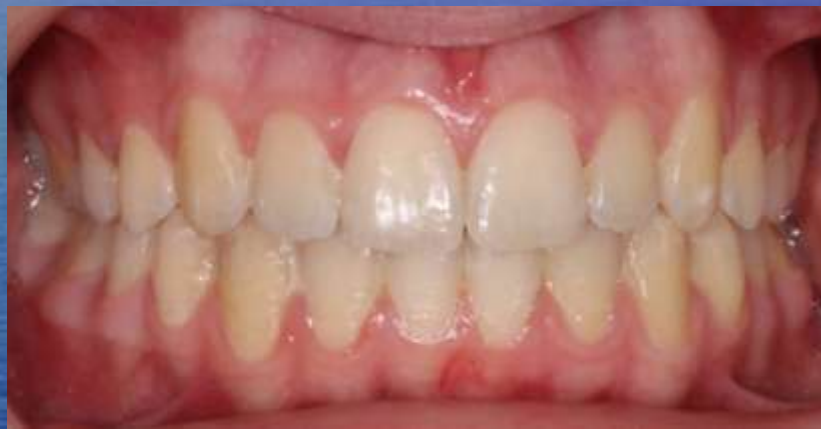
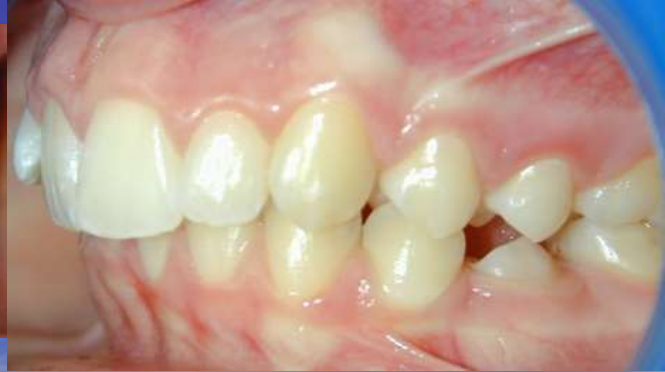
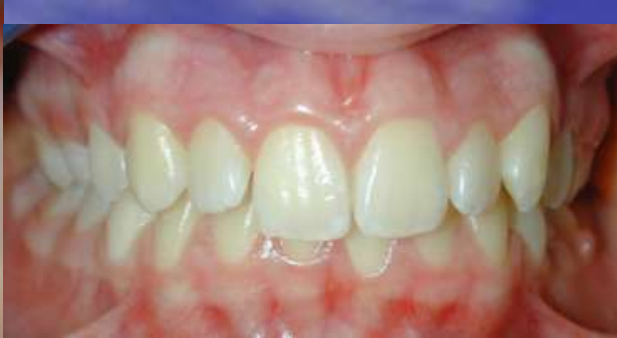Braces selfligating
14 M

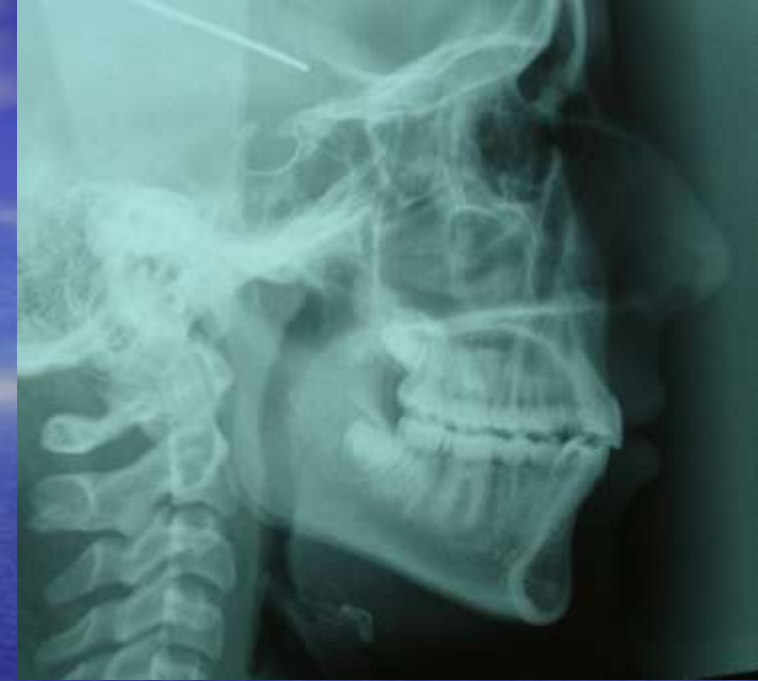




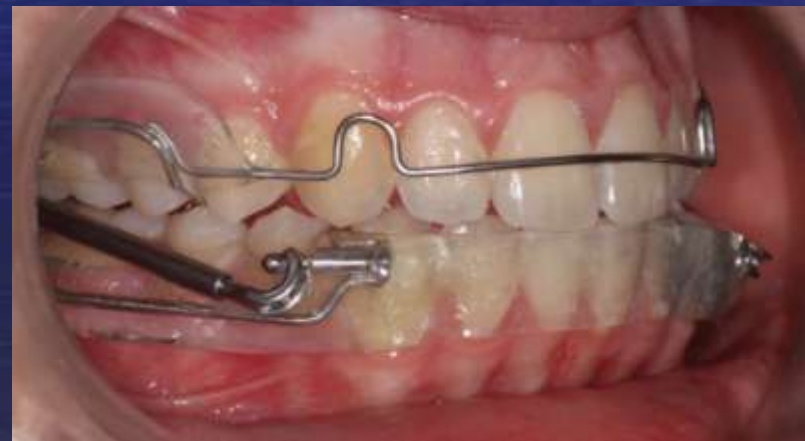
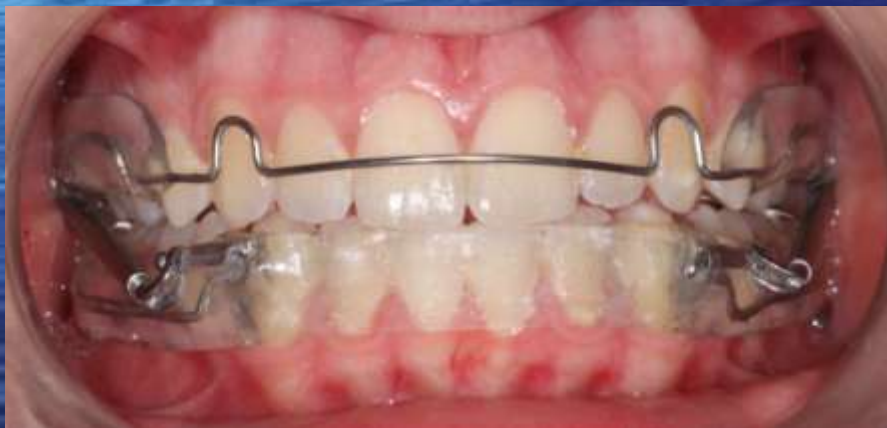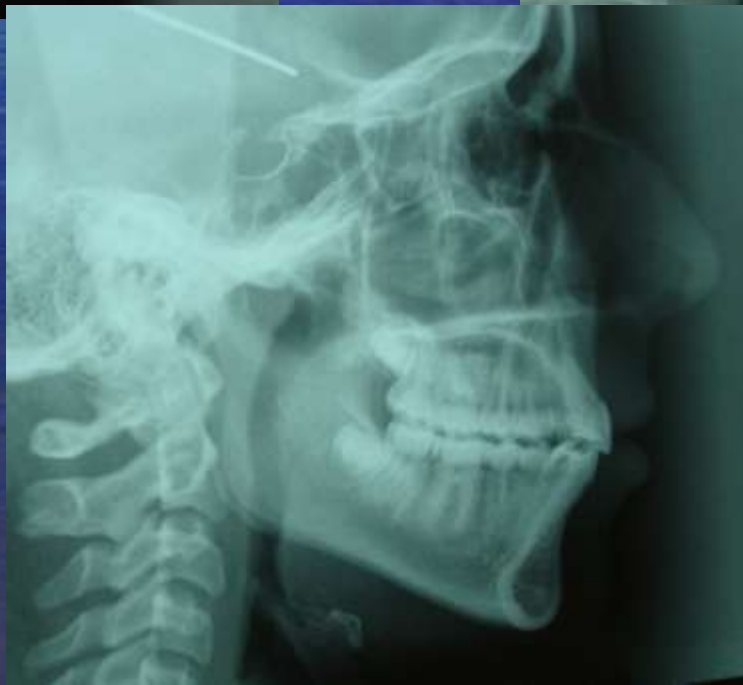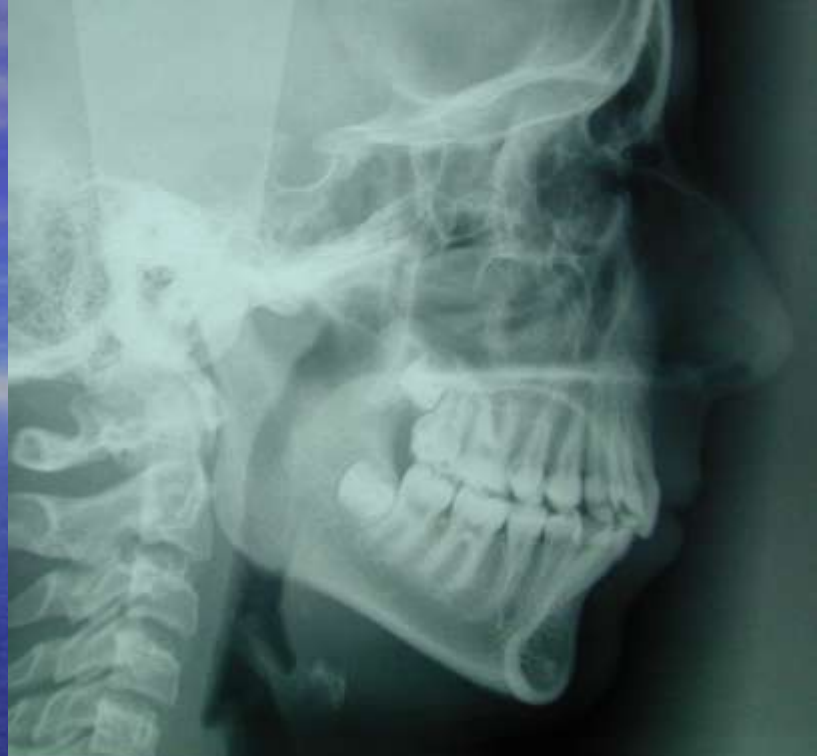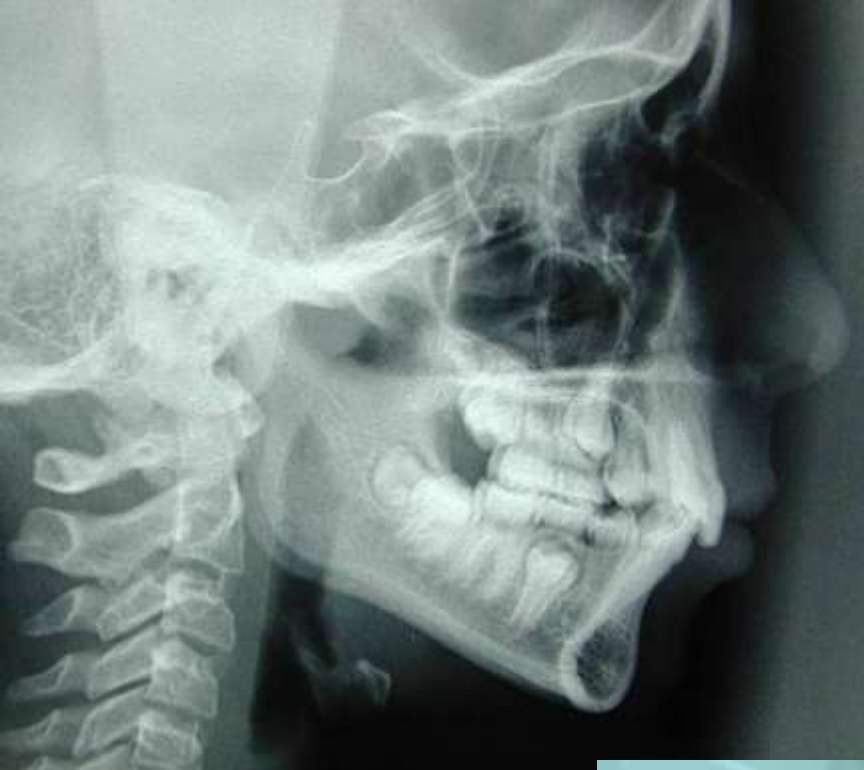PUL 10 M

Braces 14 M



Contention 4D
4D Retainer



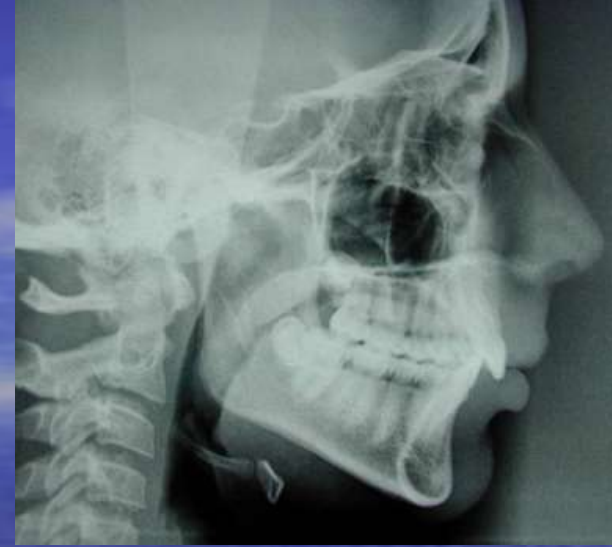


14:49:48 Centro da Radiologia

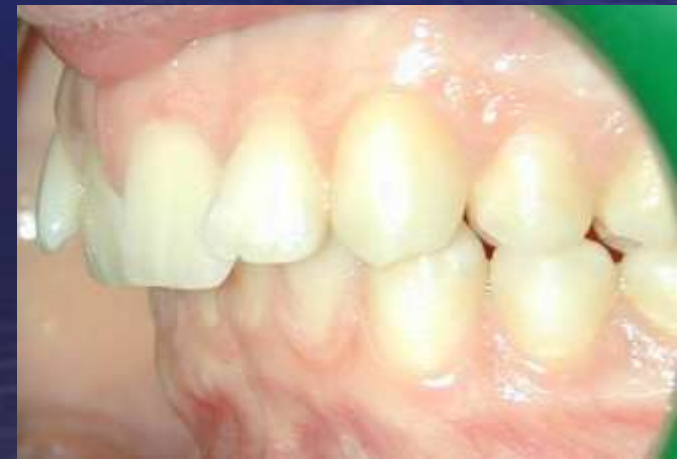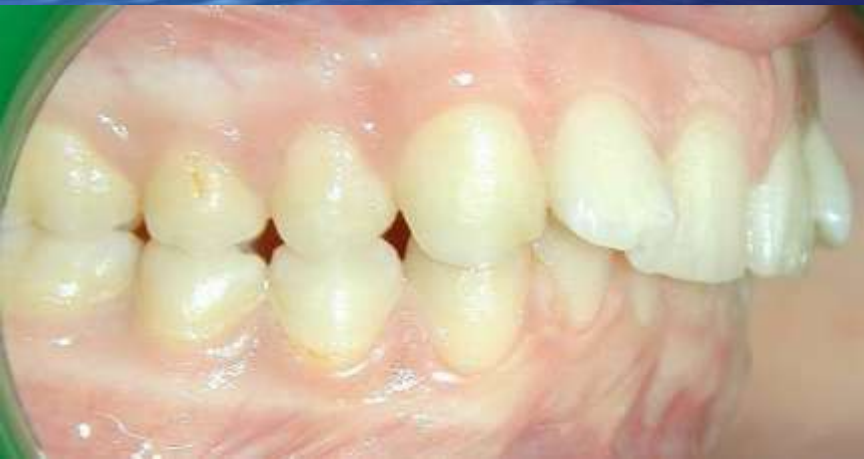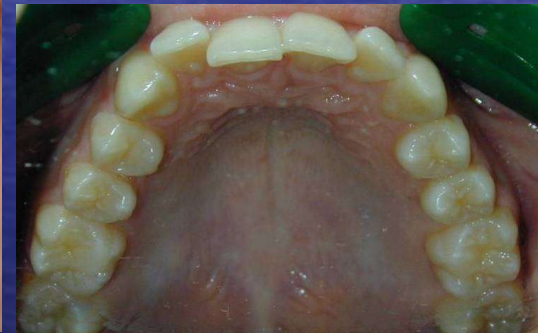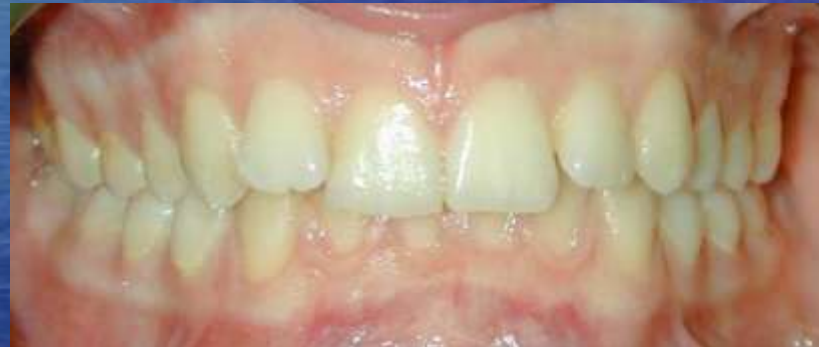Class II division 2

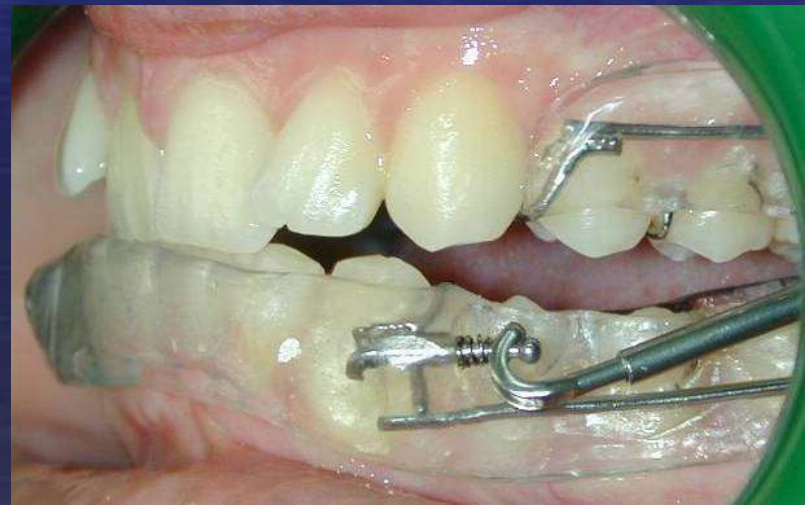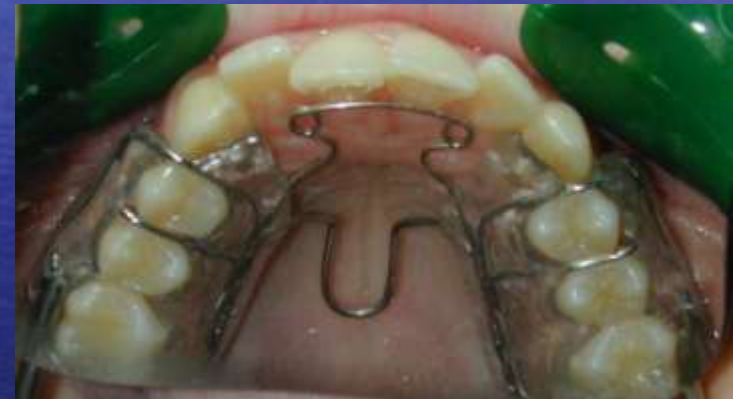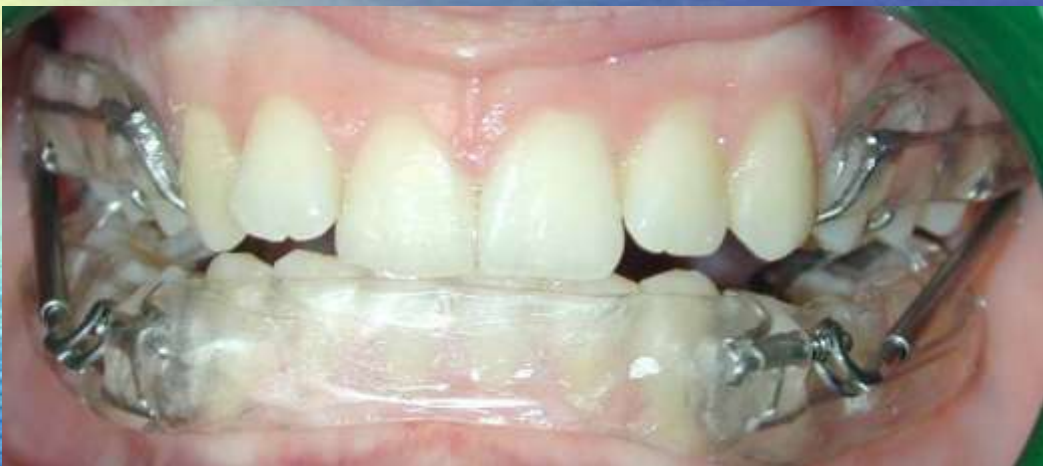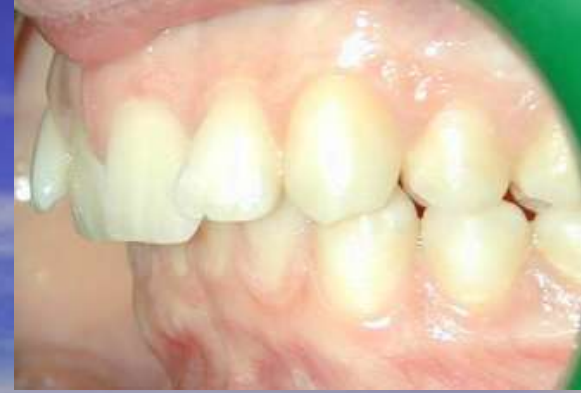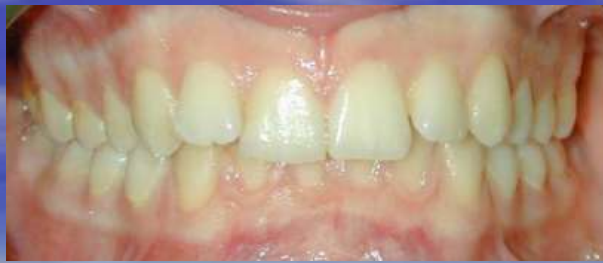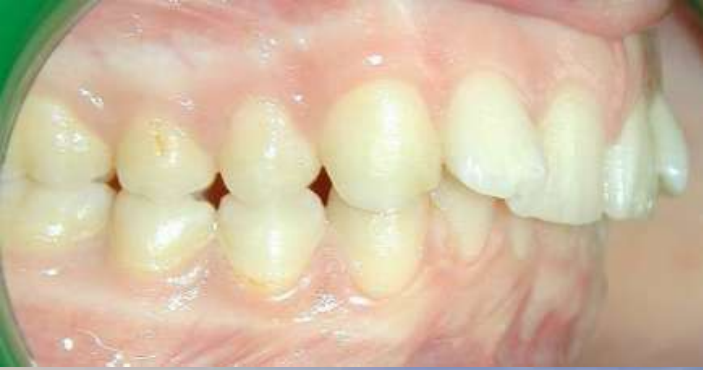Ado

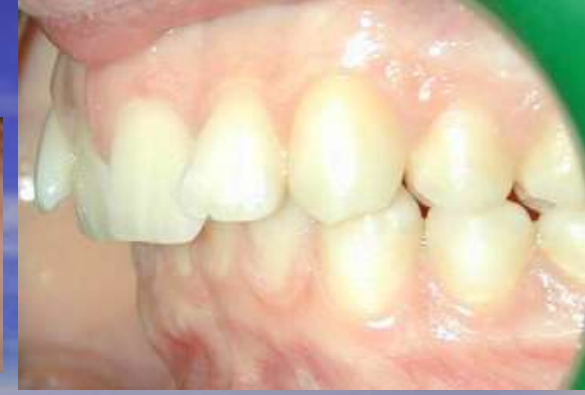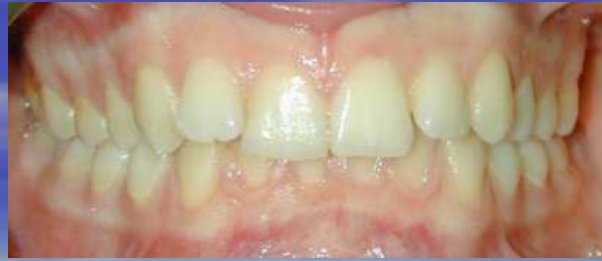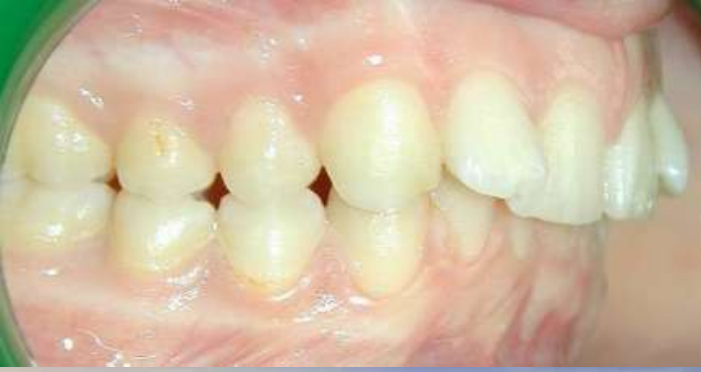PUL sans bagues



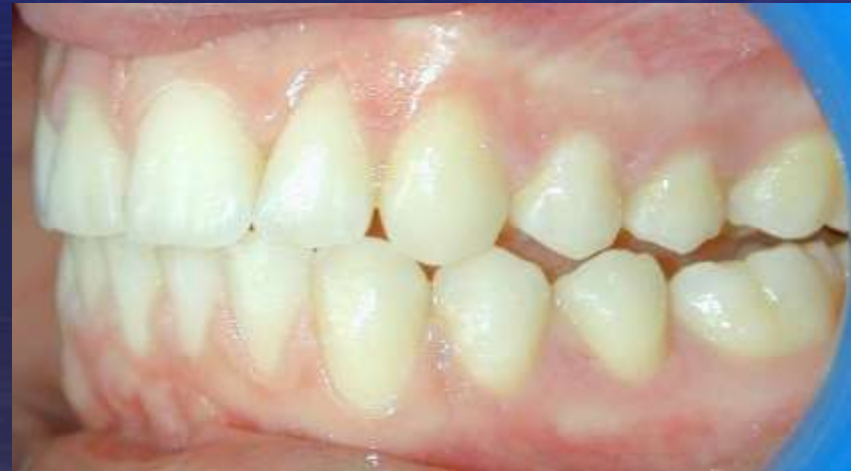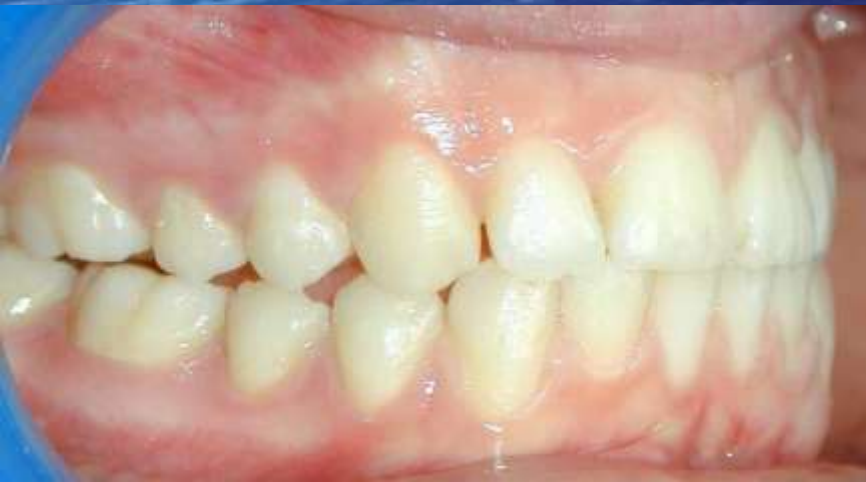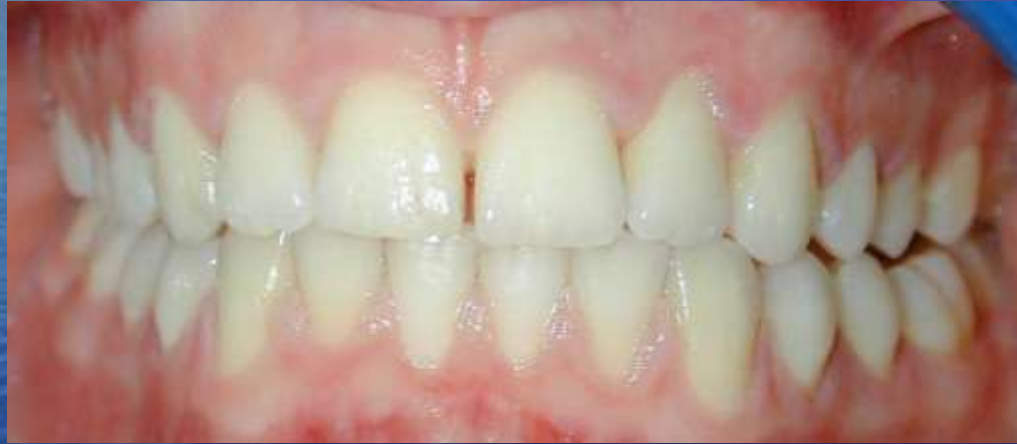7047 H 14 Y
CI II 2 (Me)

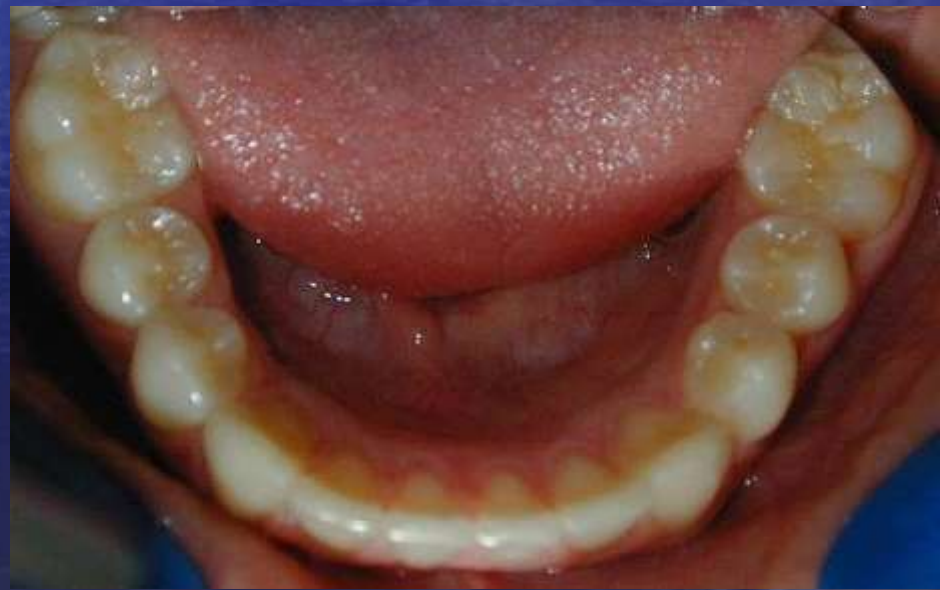
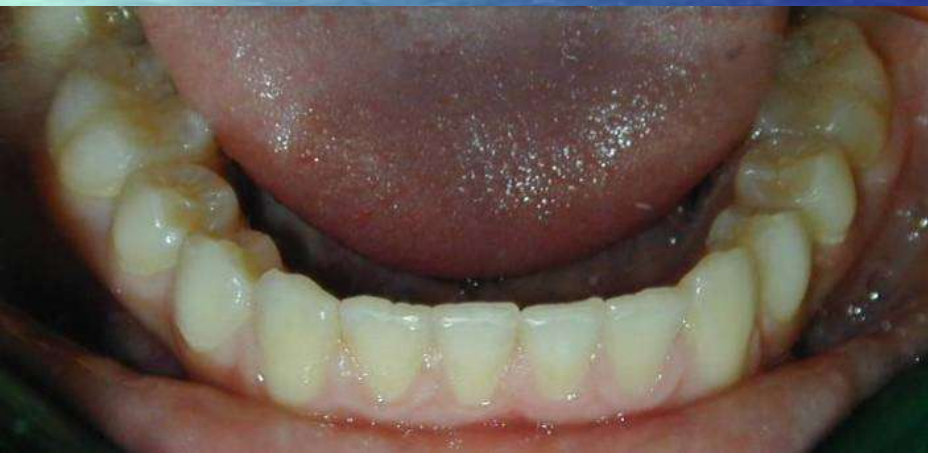
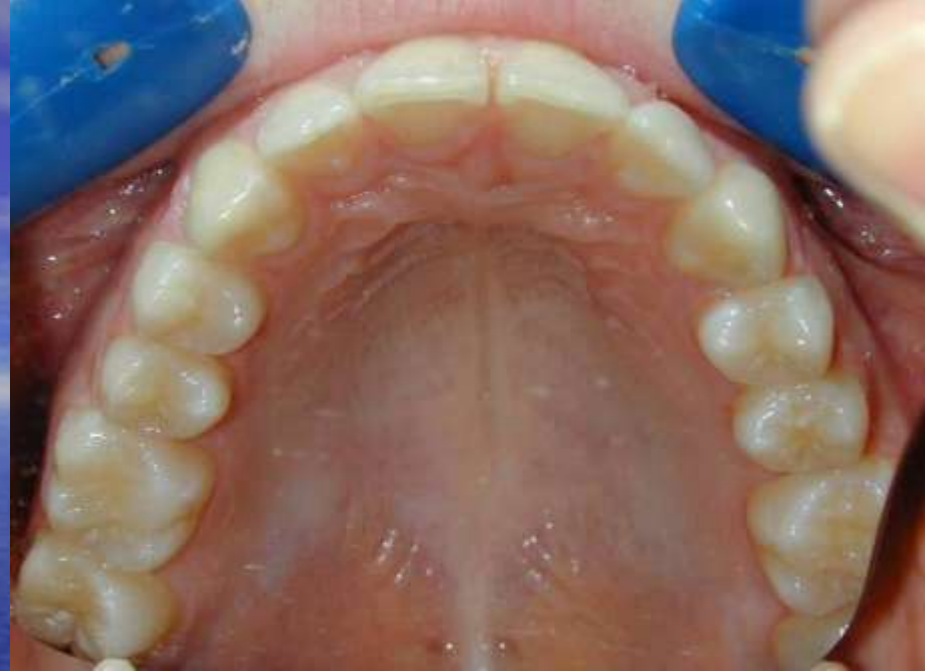
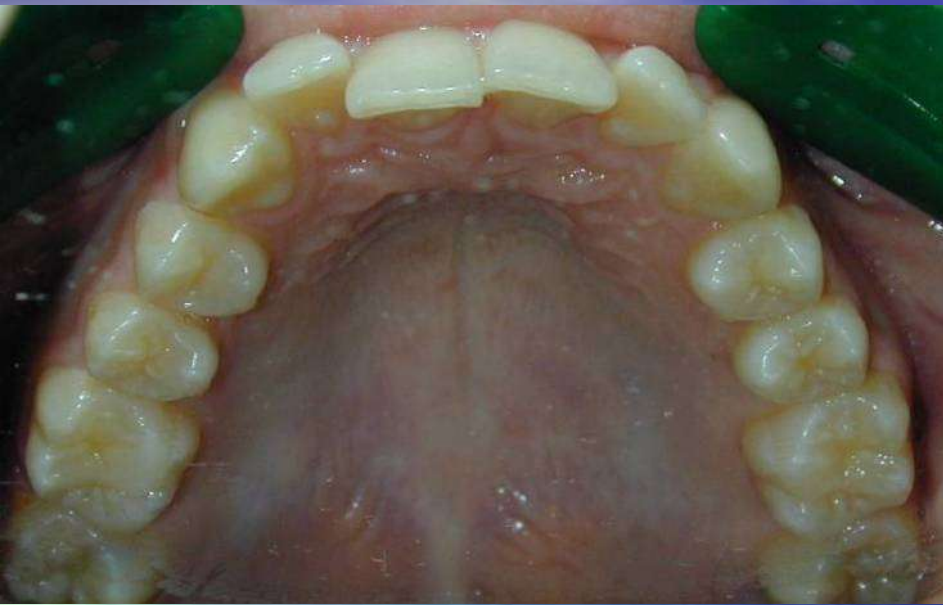


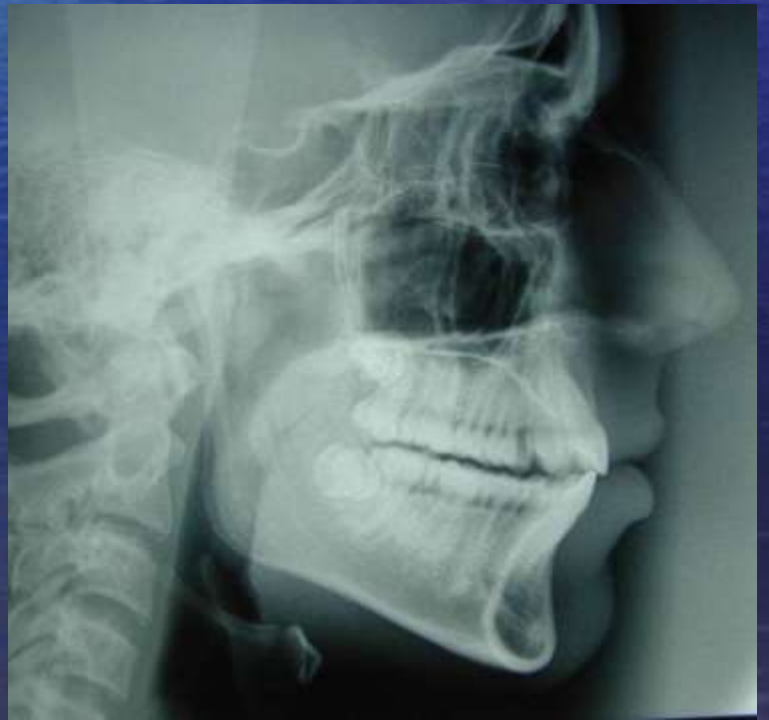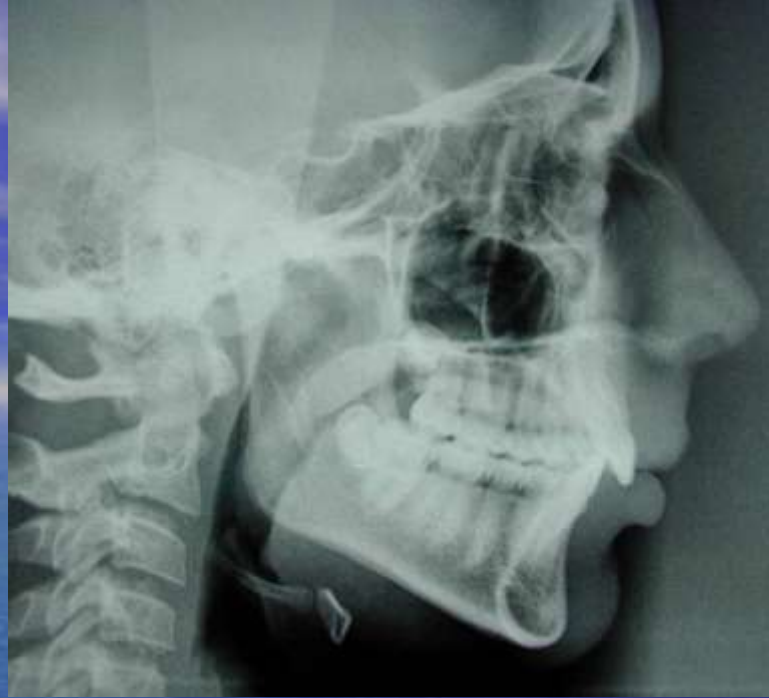PUL 6 M
+Port en
contention



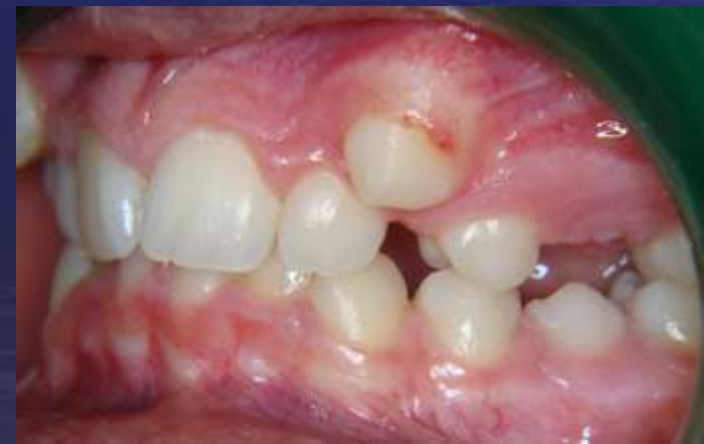
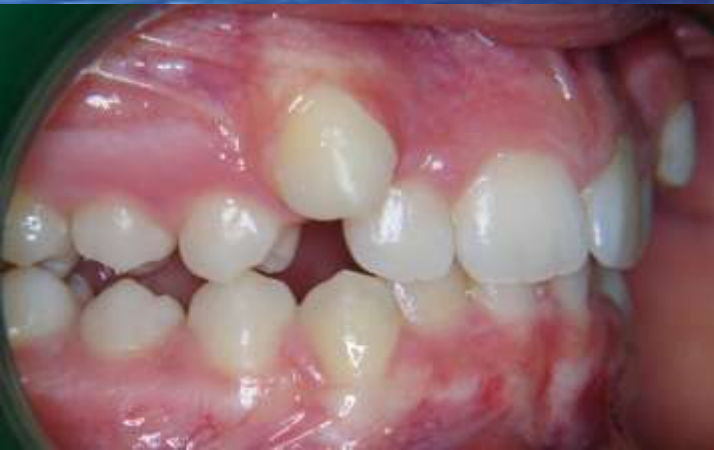
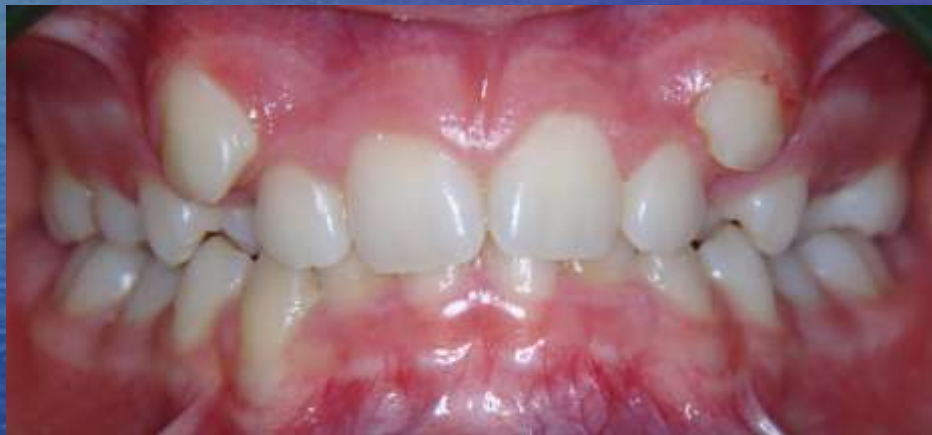
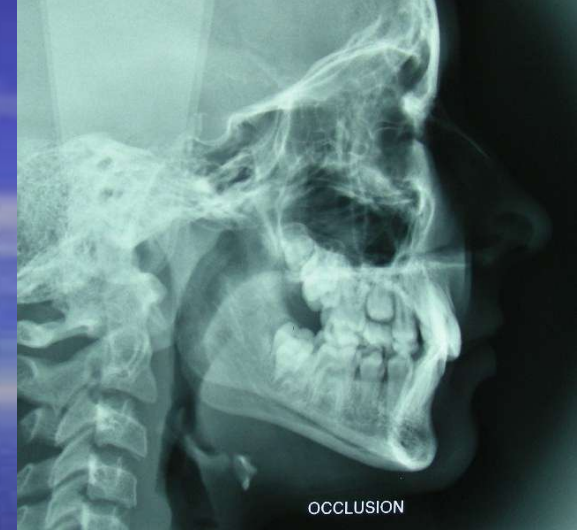
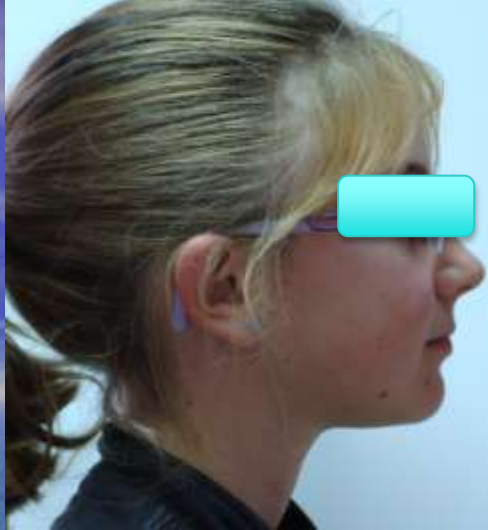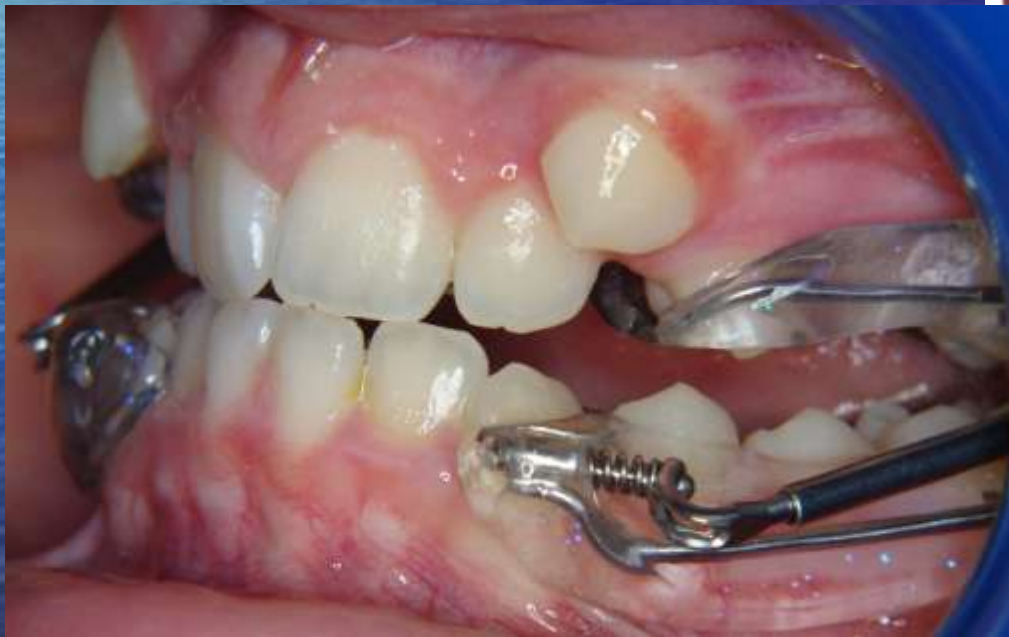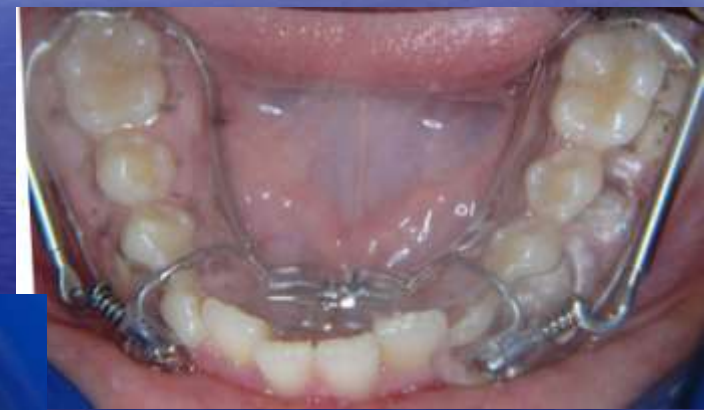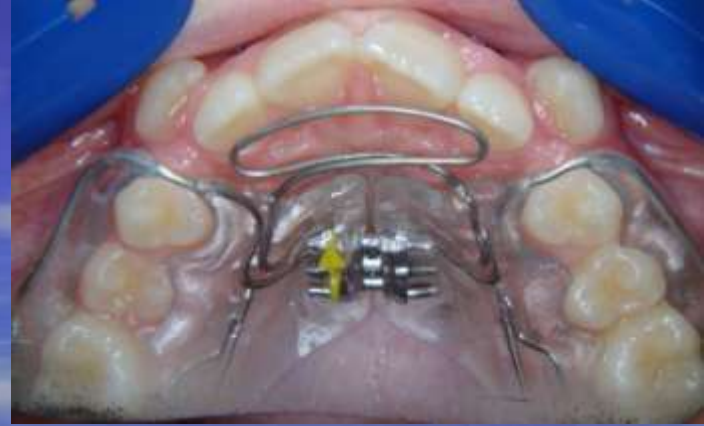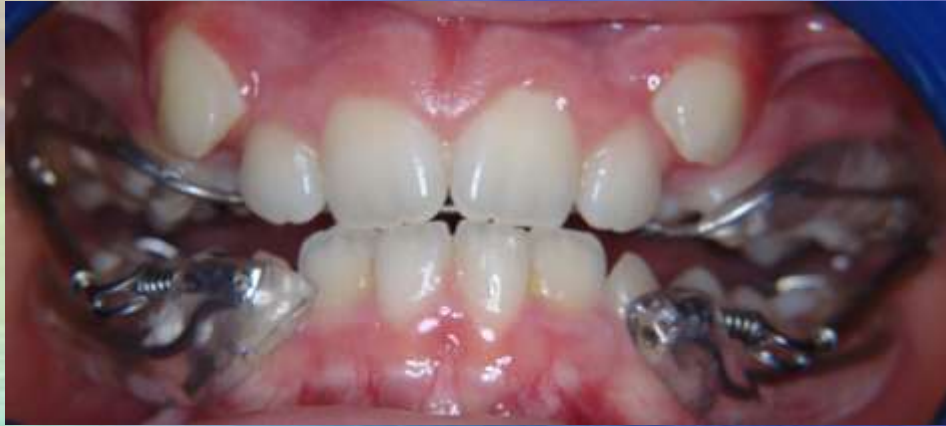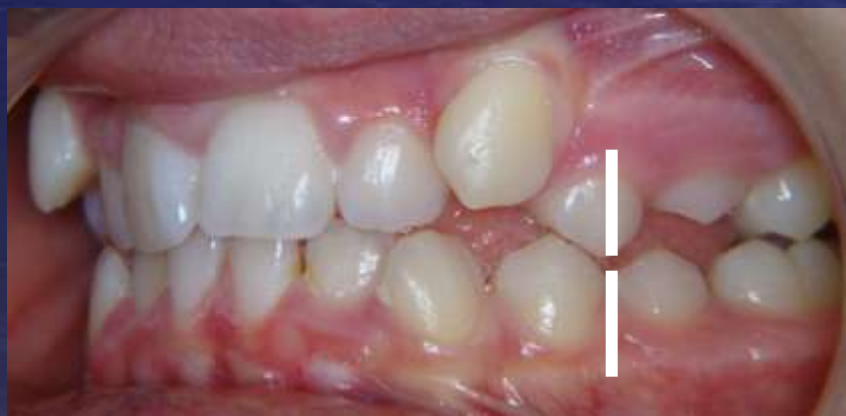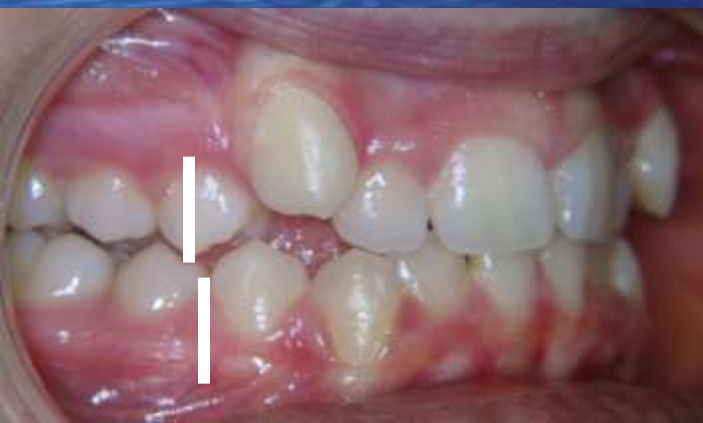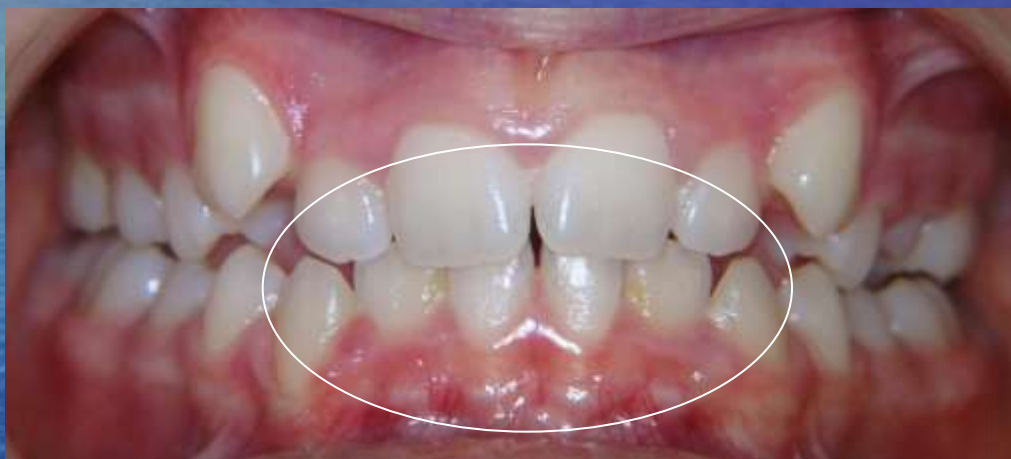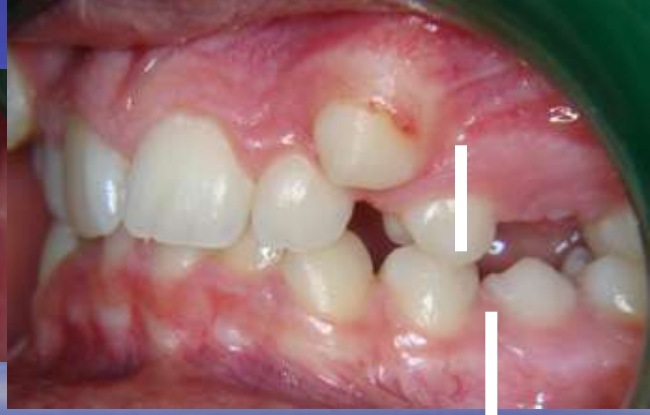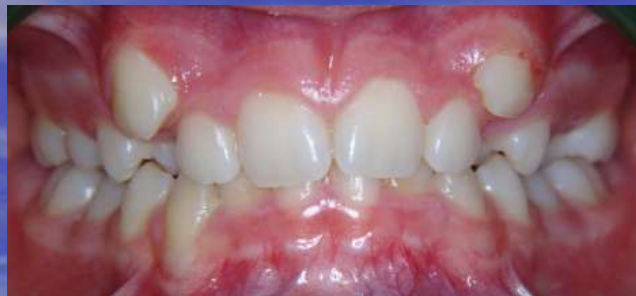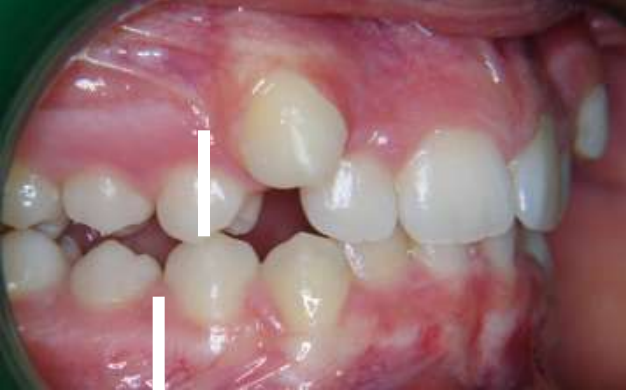Class II div 2 Maxillary crowding

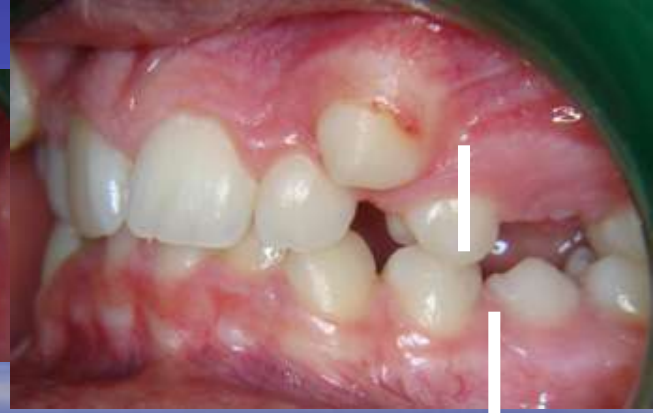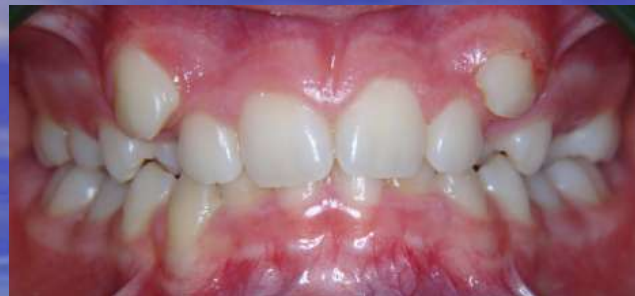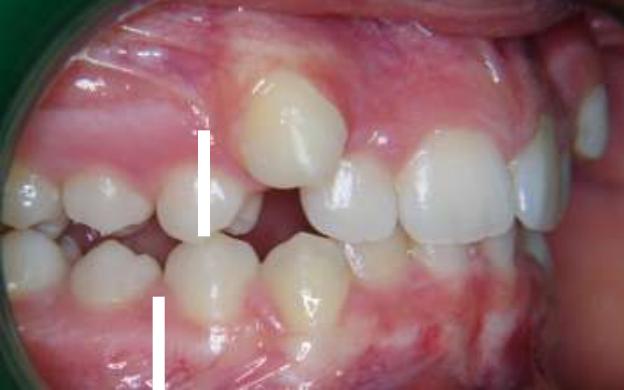Mandibular Anchorage
Ancrage Mandibulaire

Case B.
12 Y

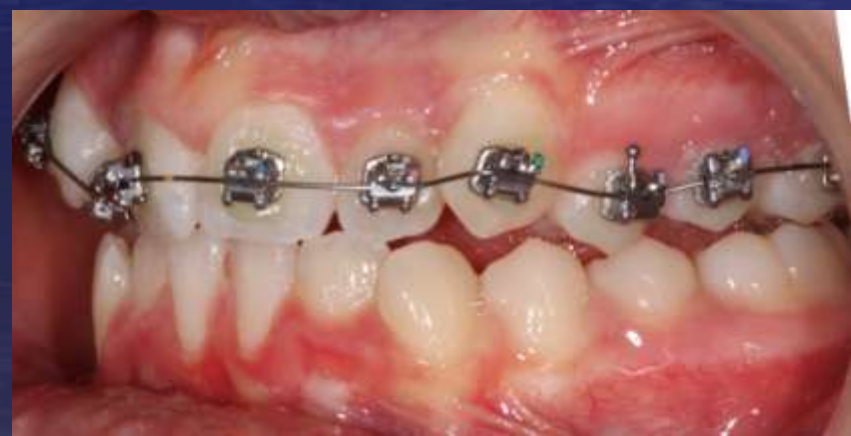
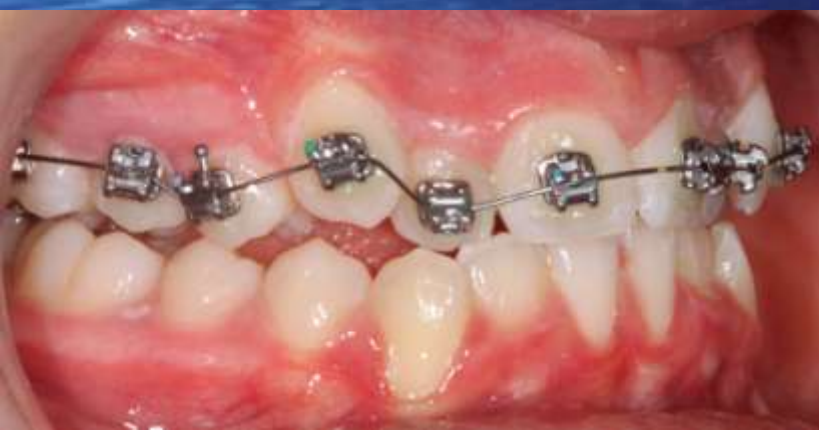
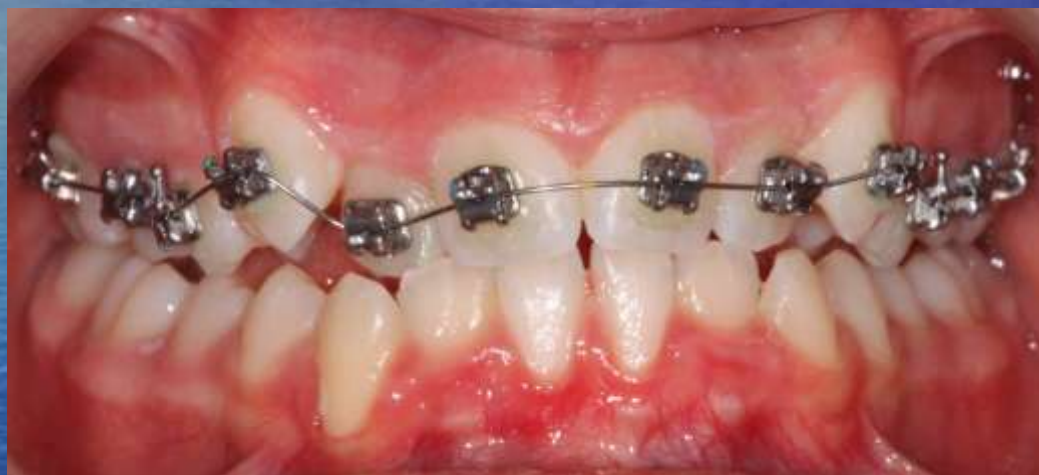


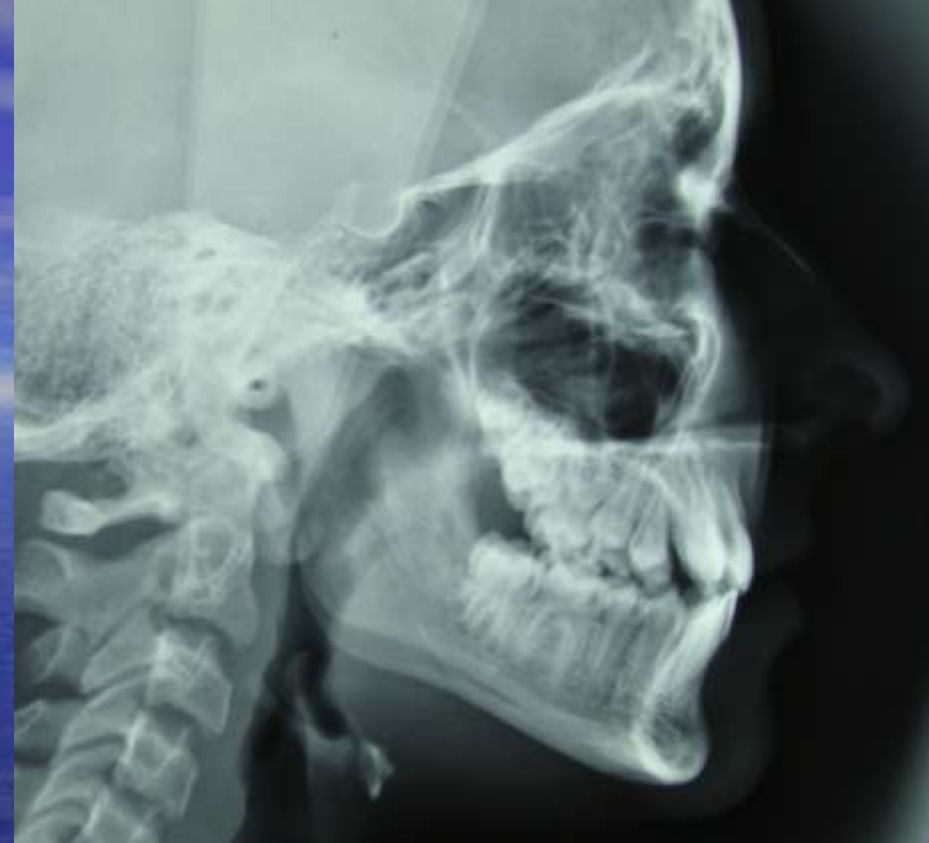
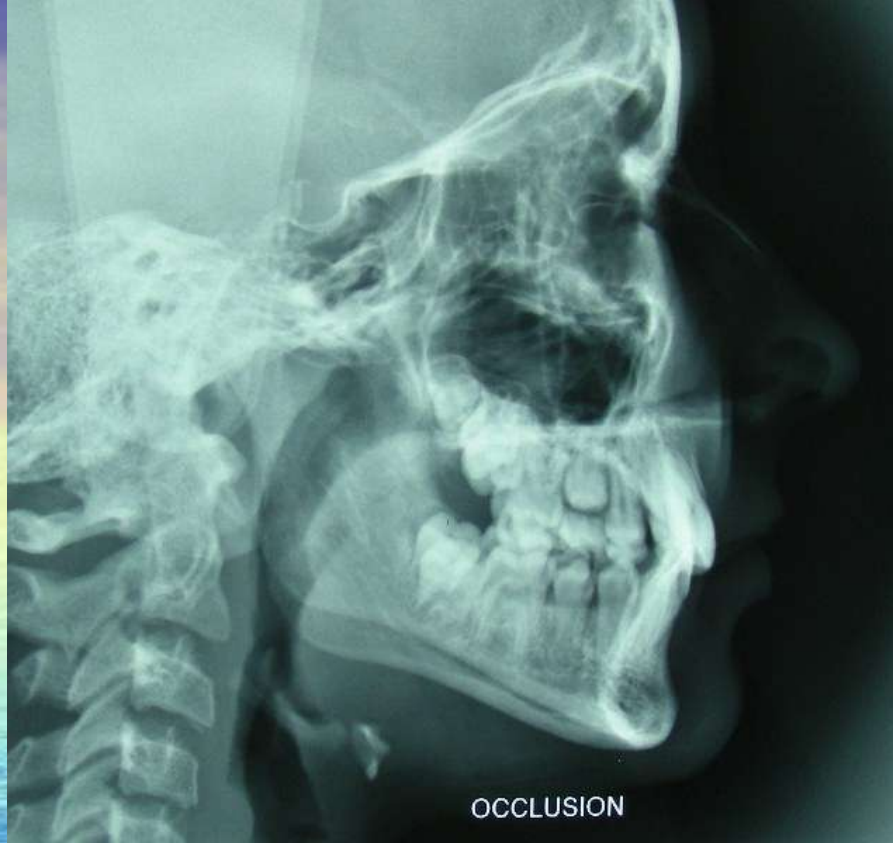

PUL 9Mois
PUL 9 Months

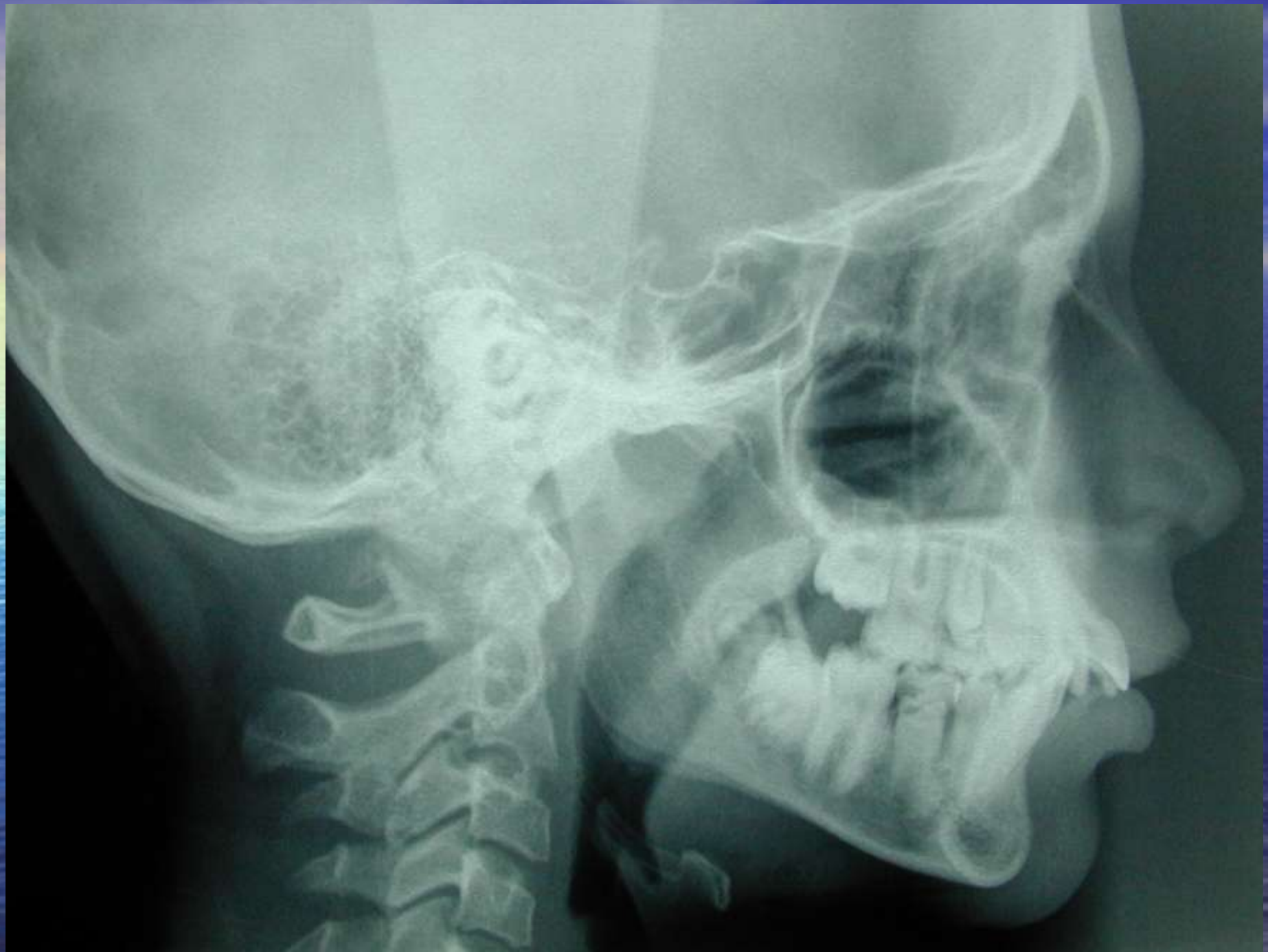


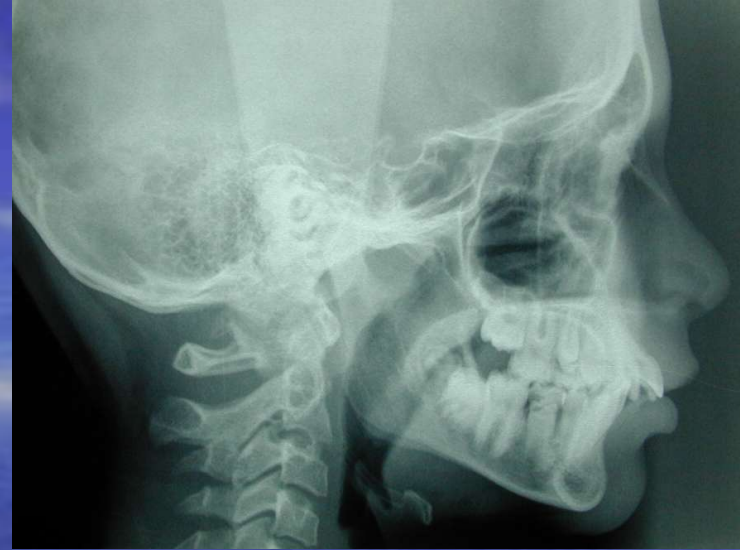
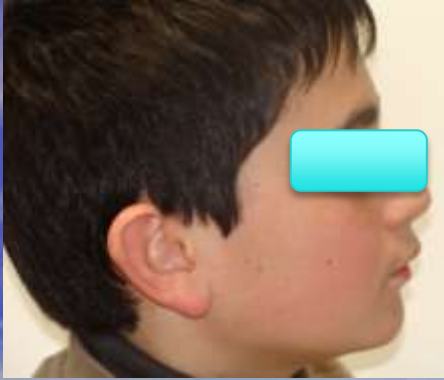Avant –Après PUL

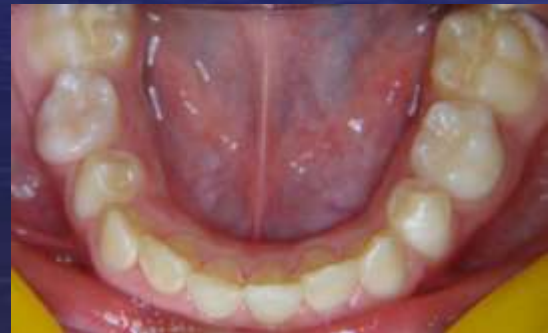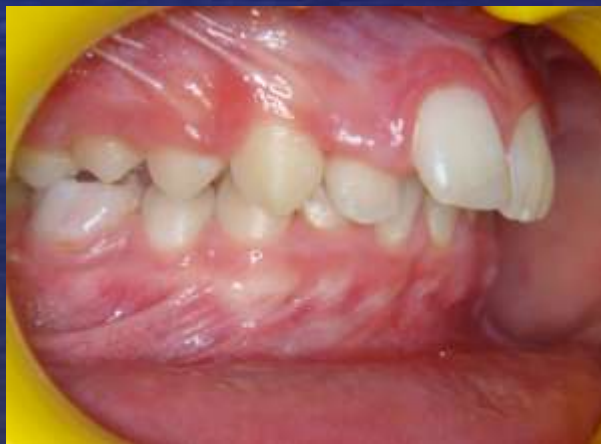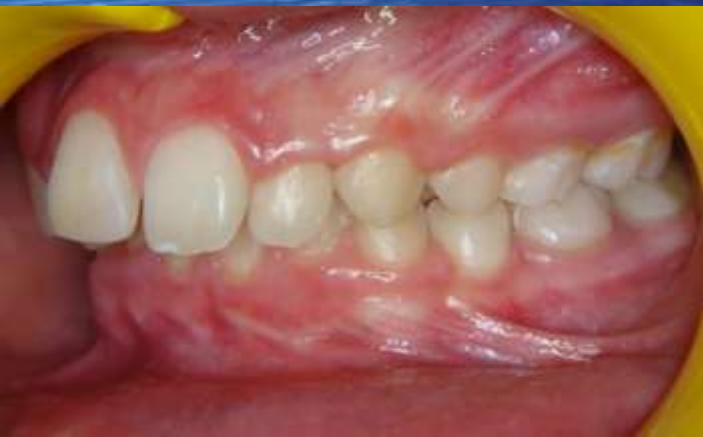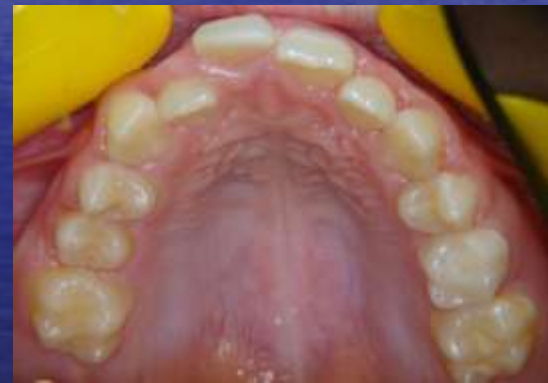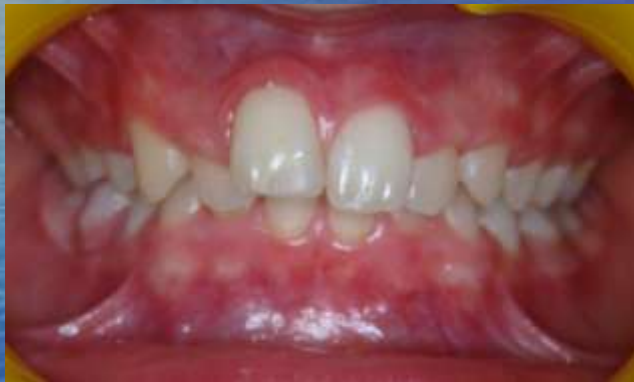Classe II

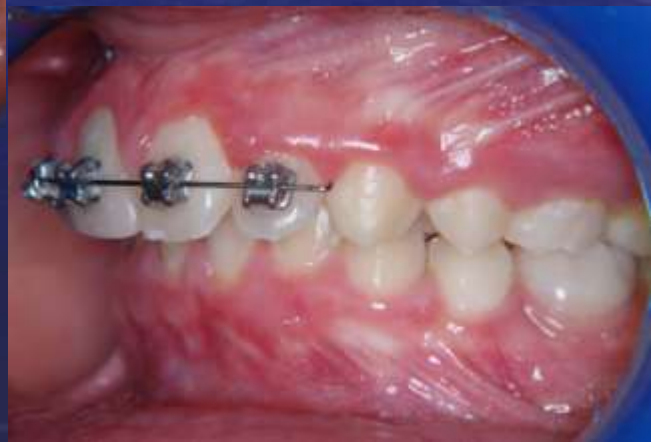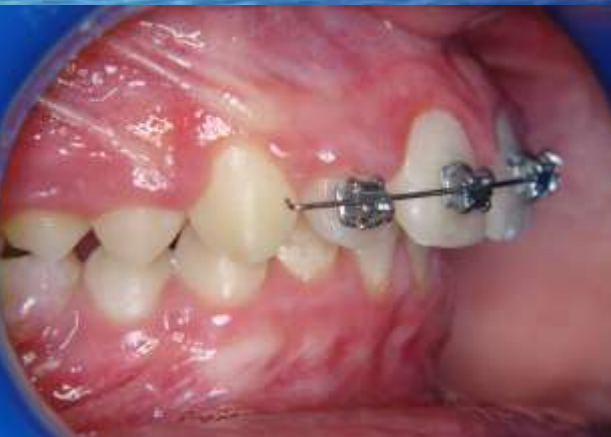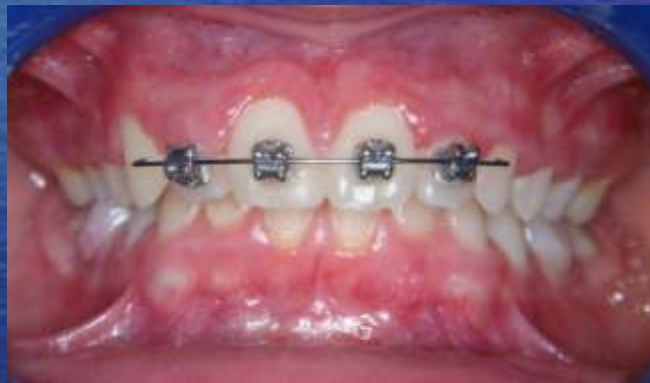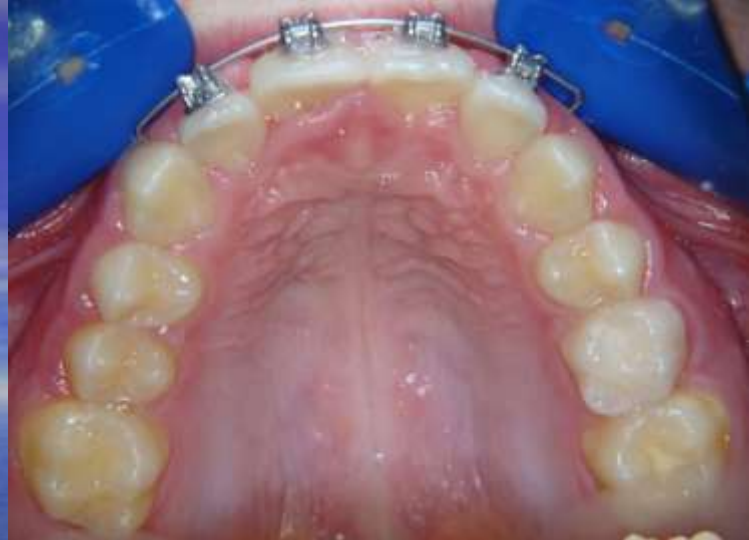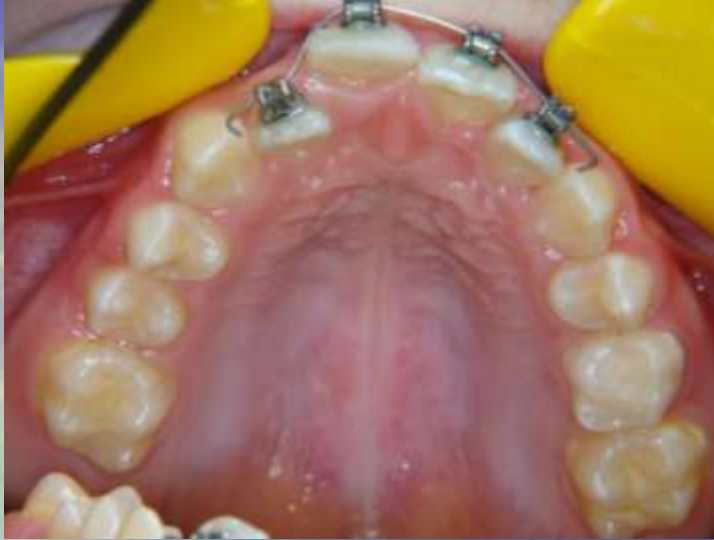Alignement 4 incisives avant PUL
Upper Incisors alignment before PUL

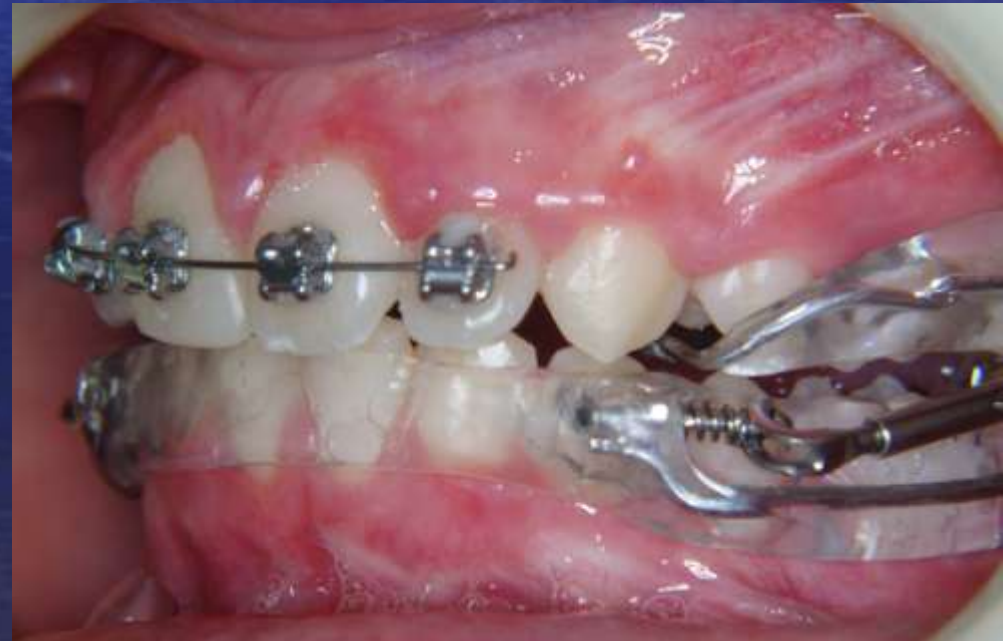
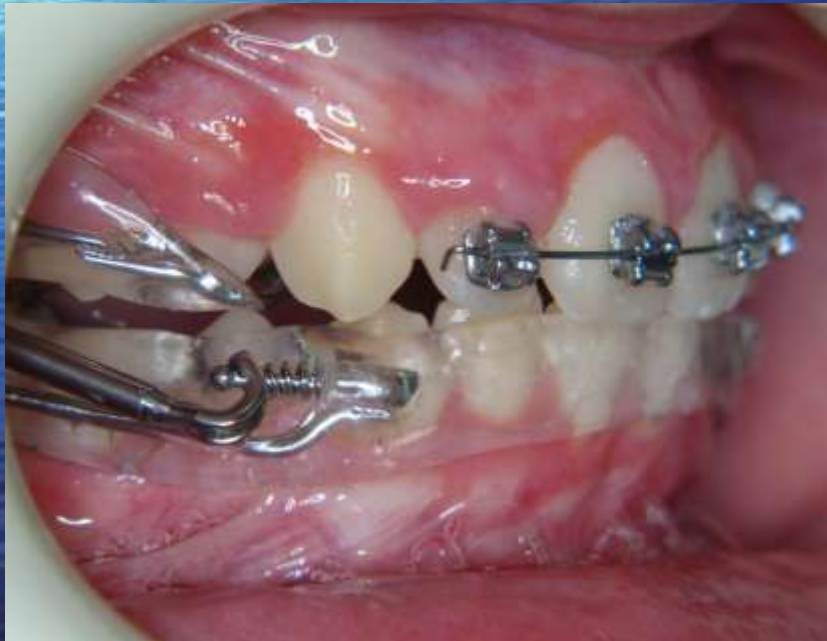
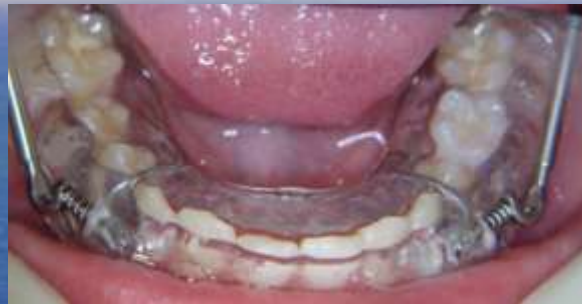
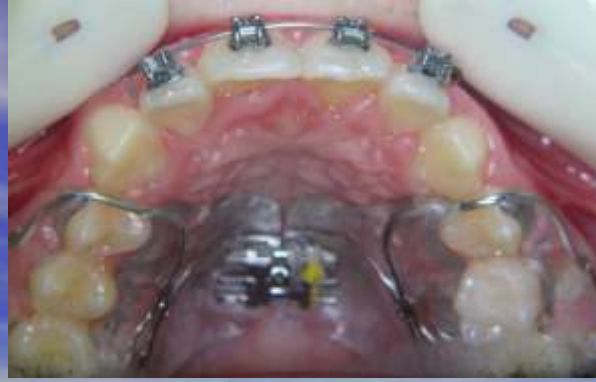
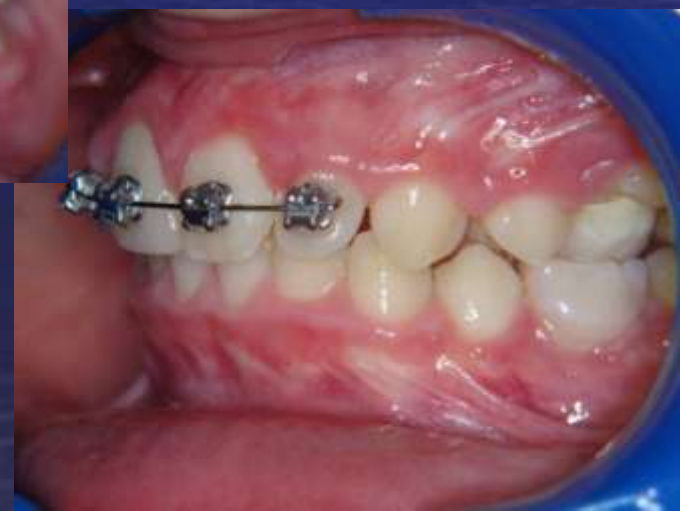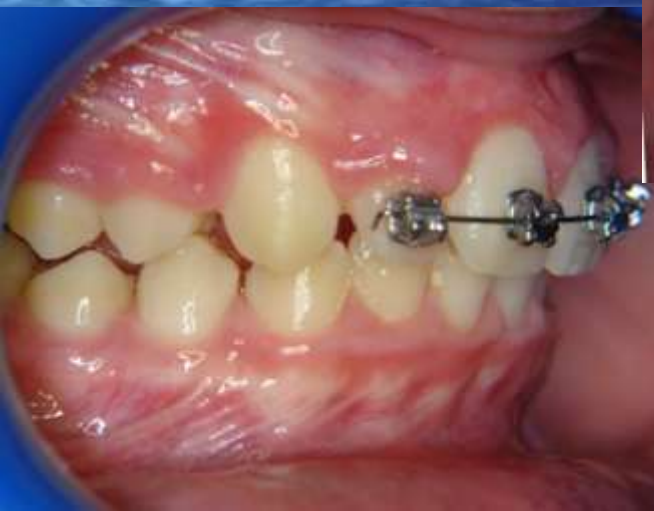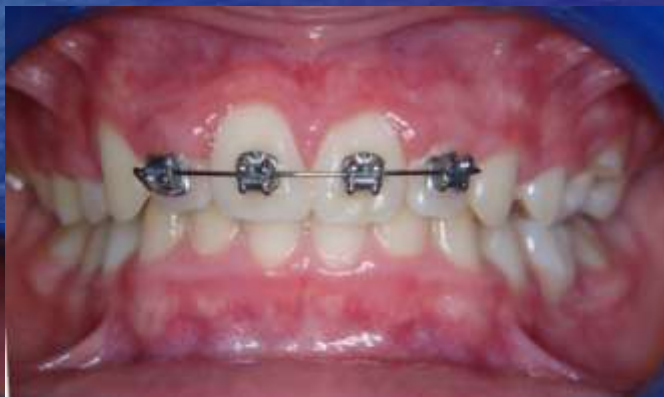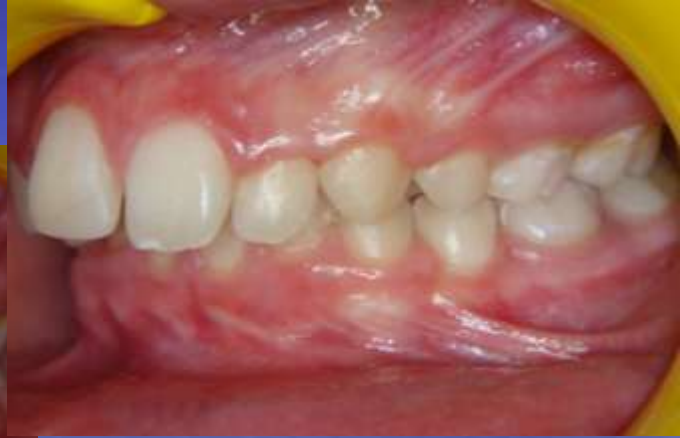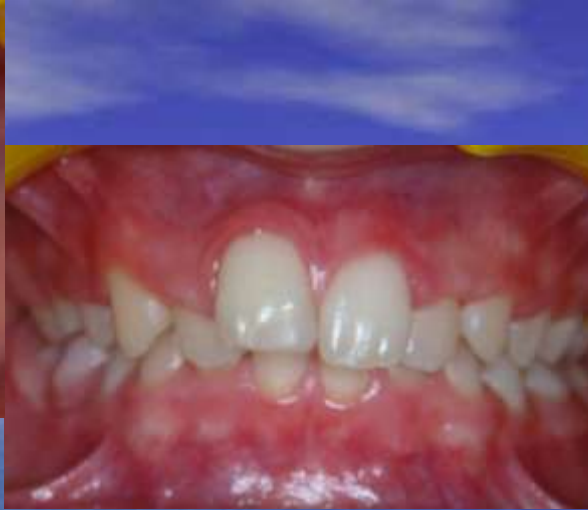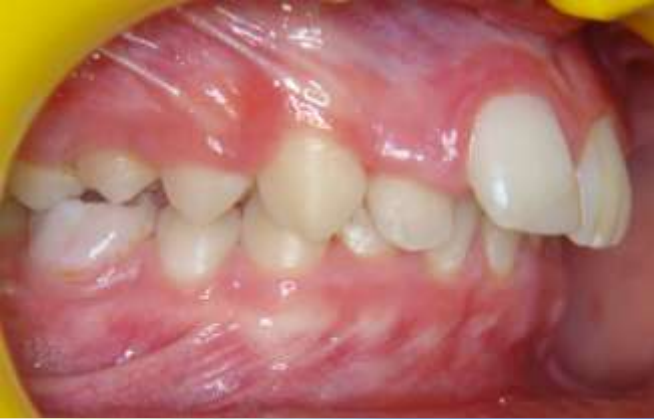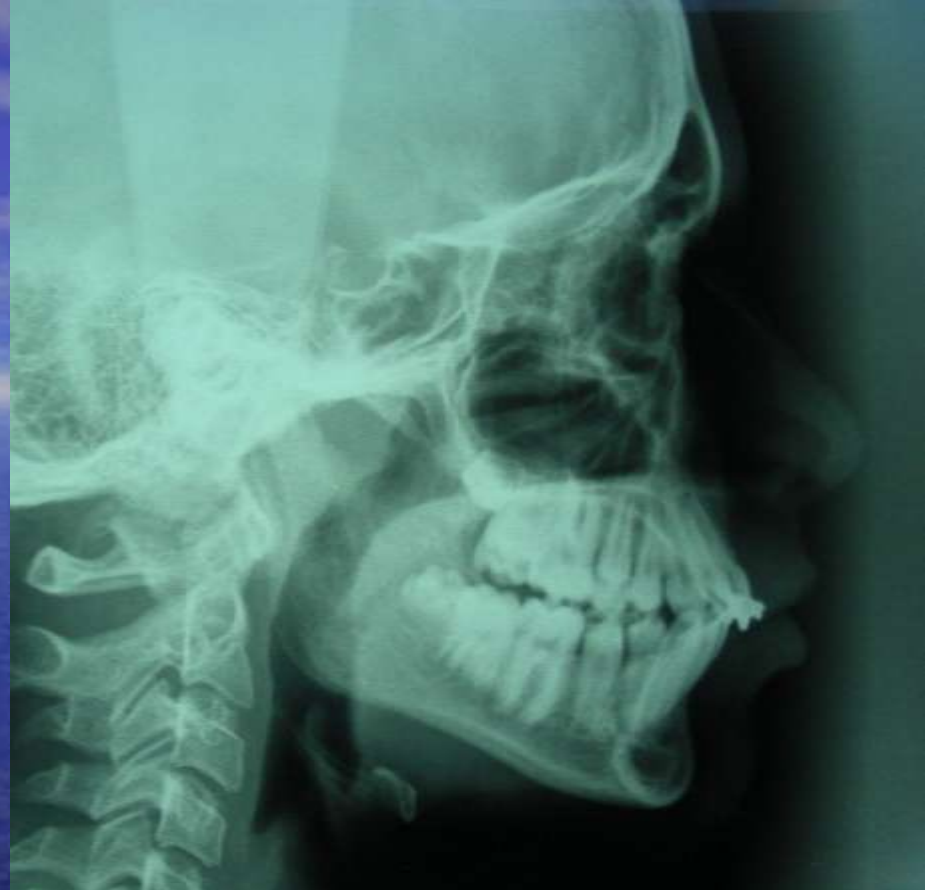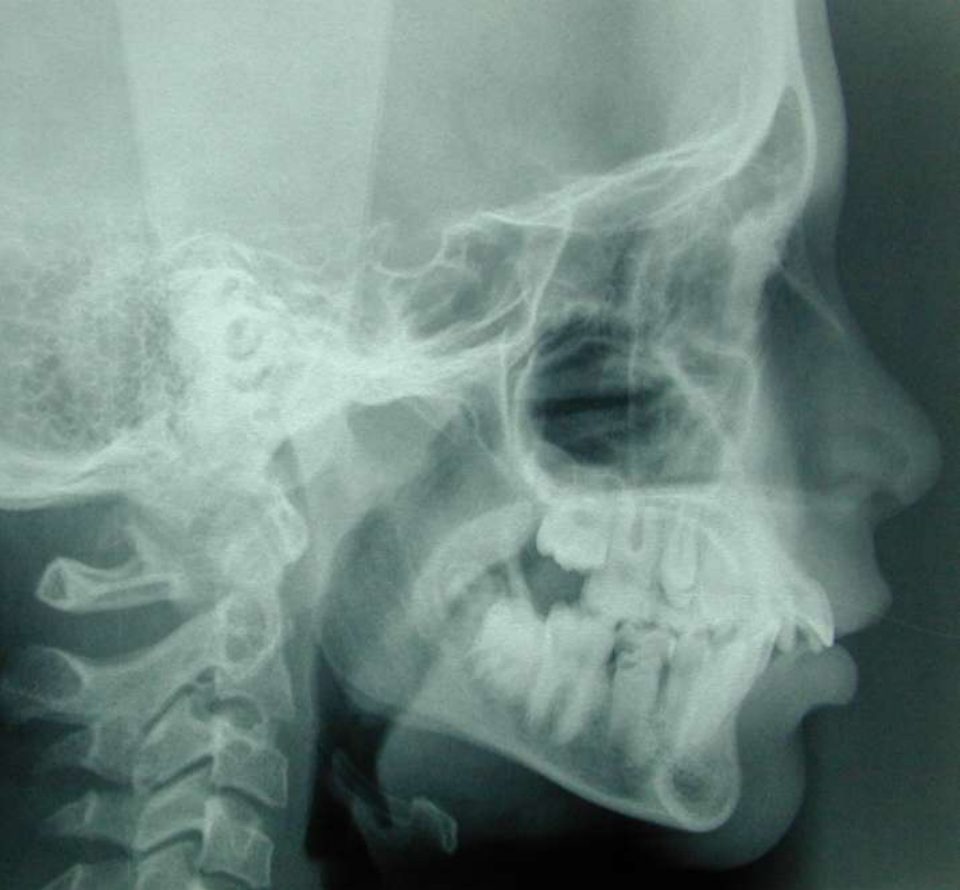m.11 ans

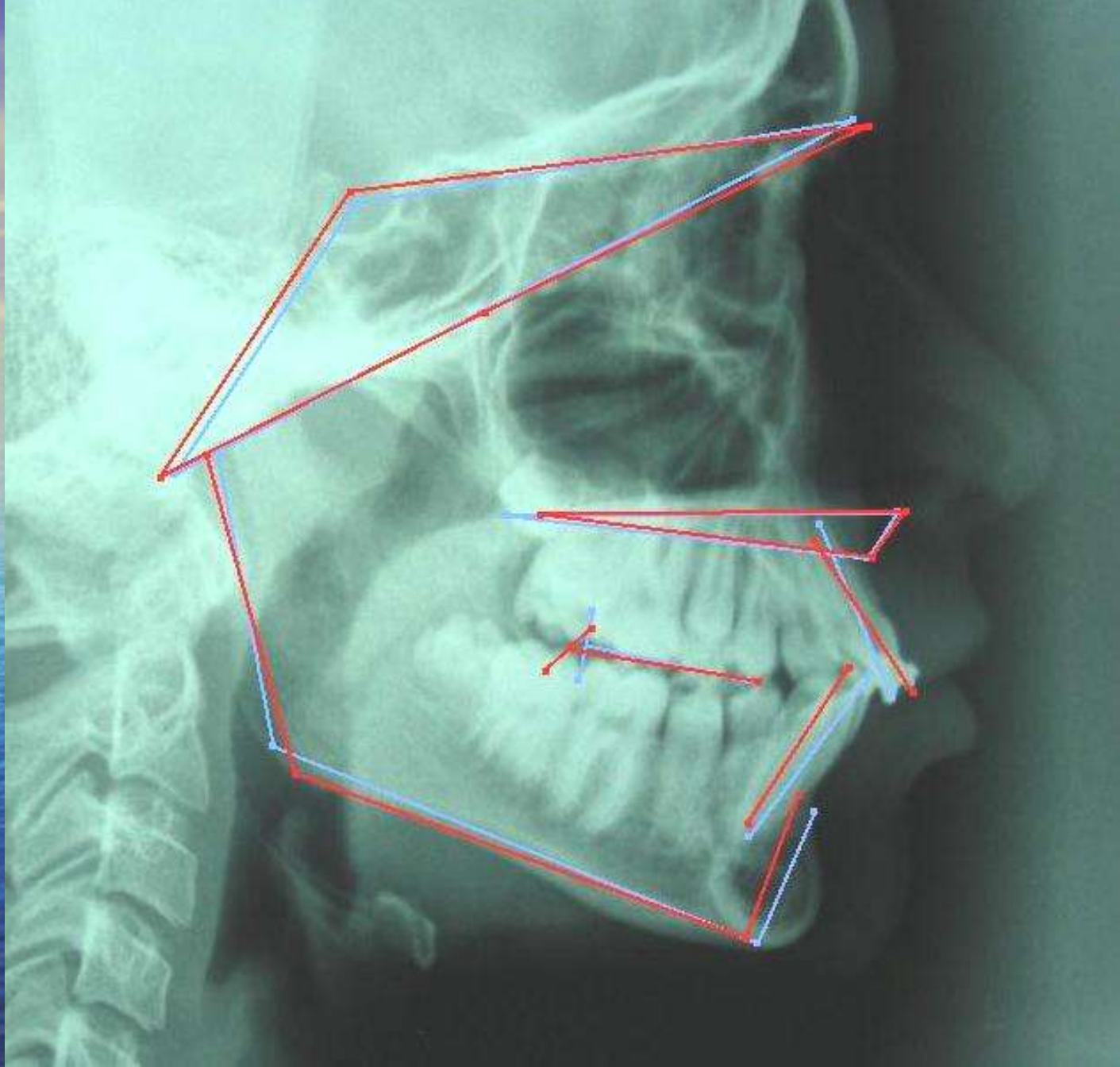


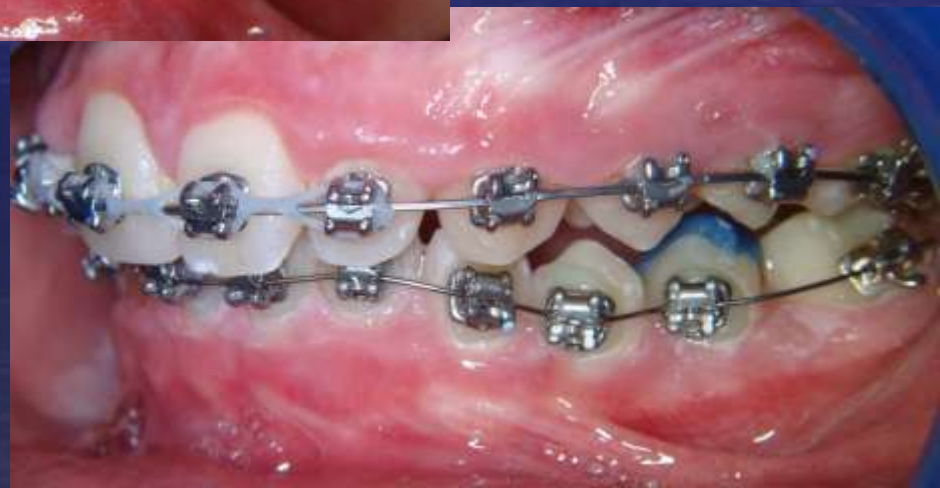
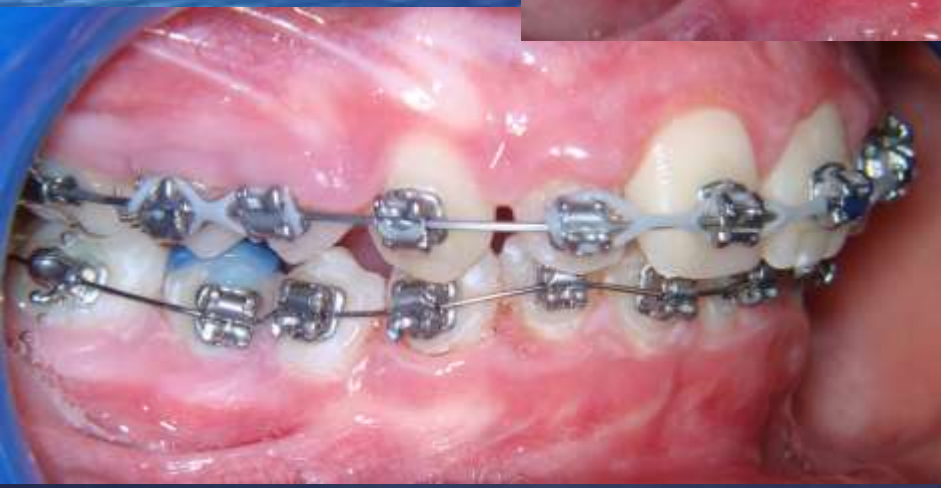
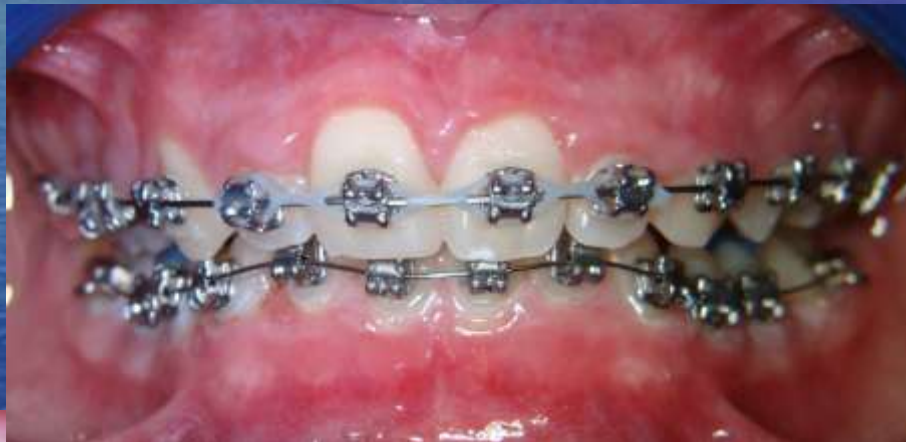
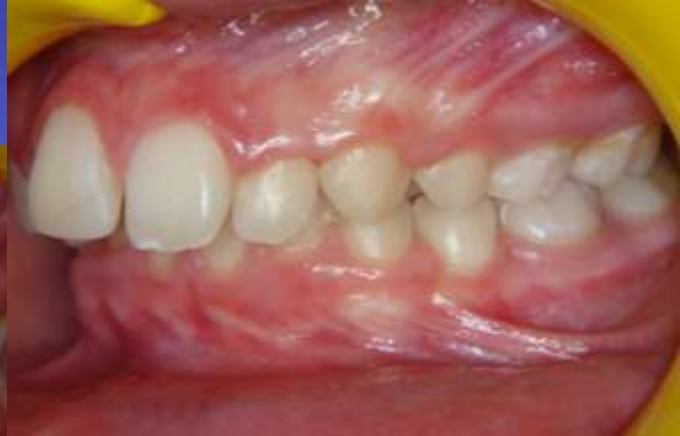


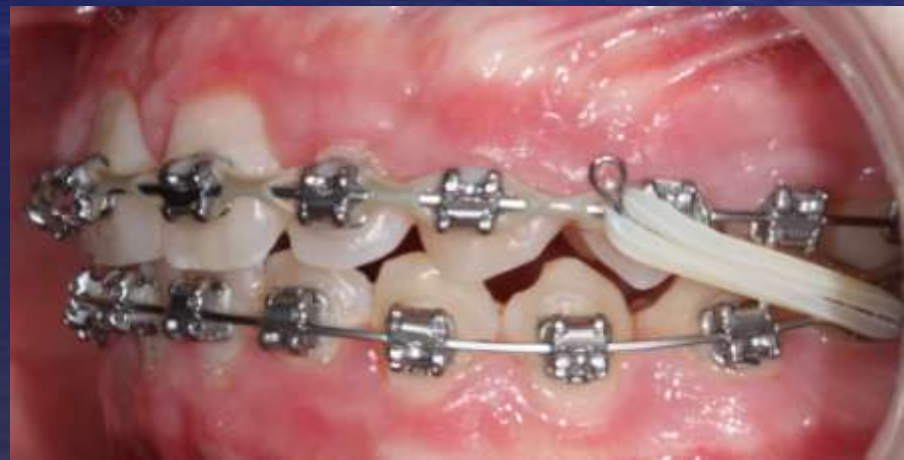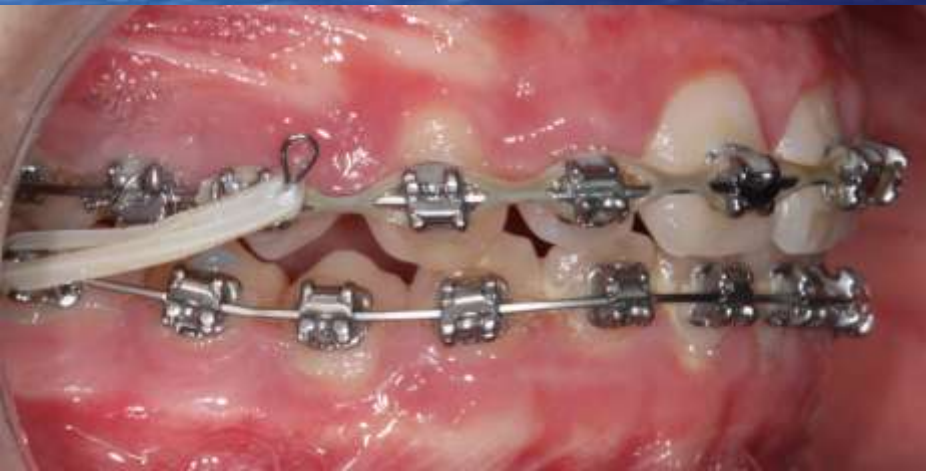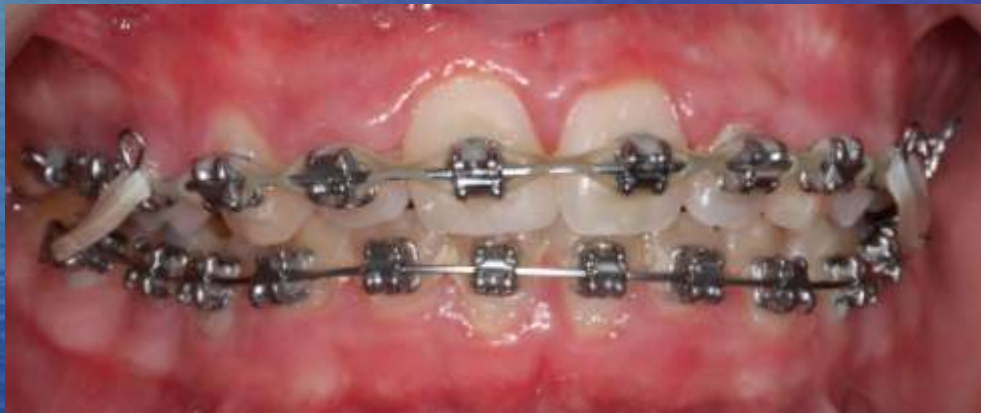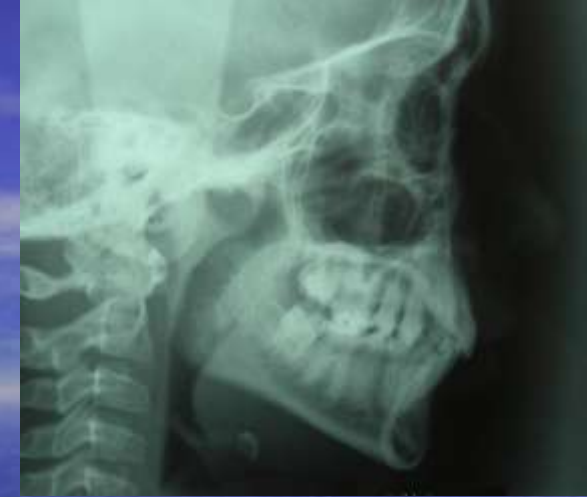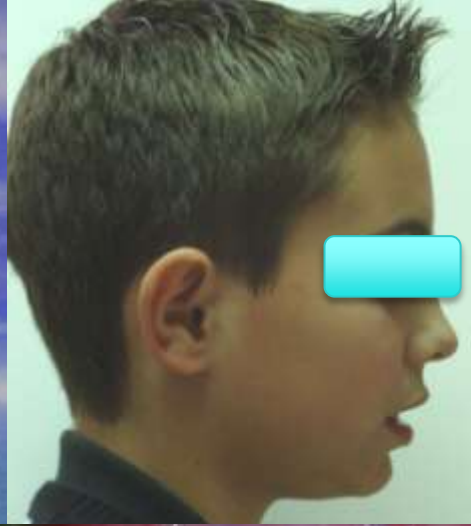






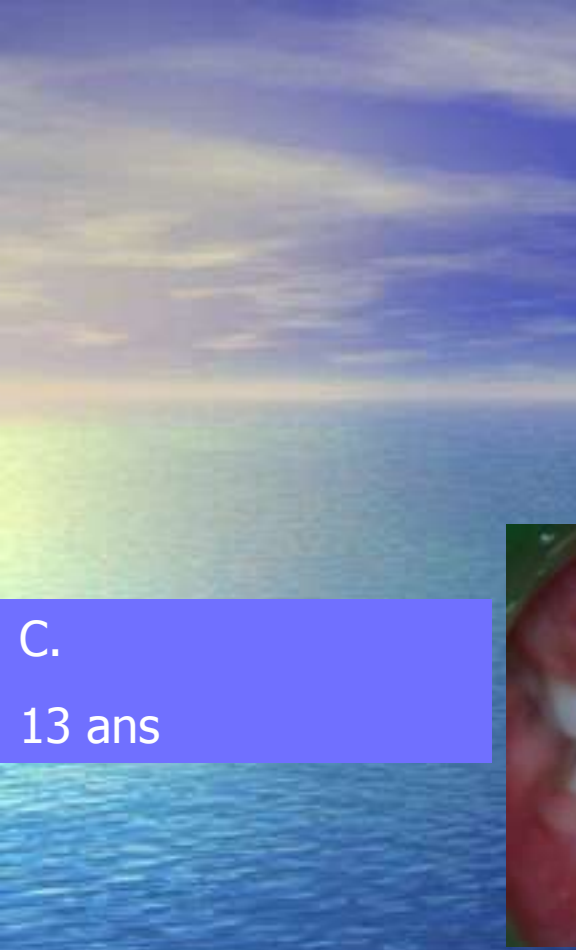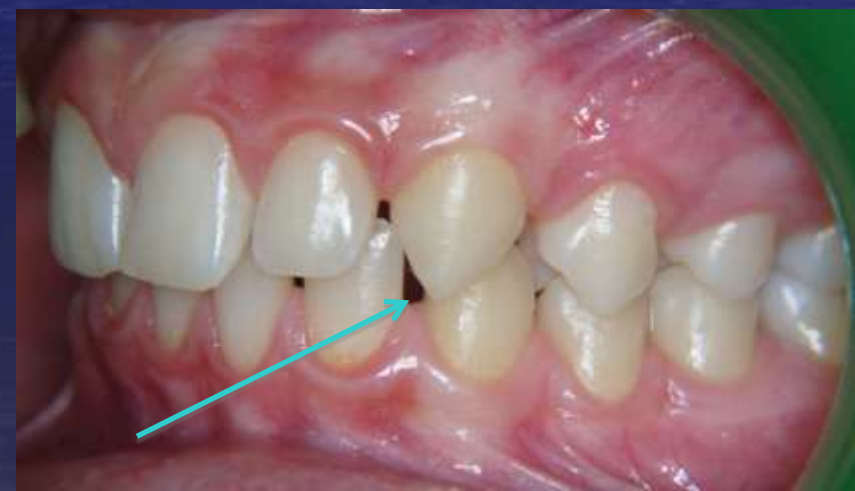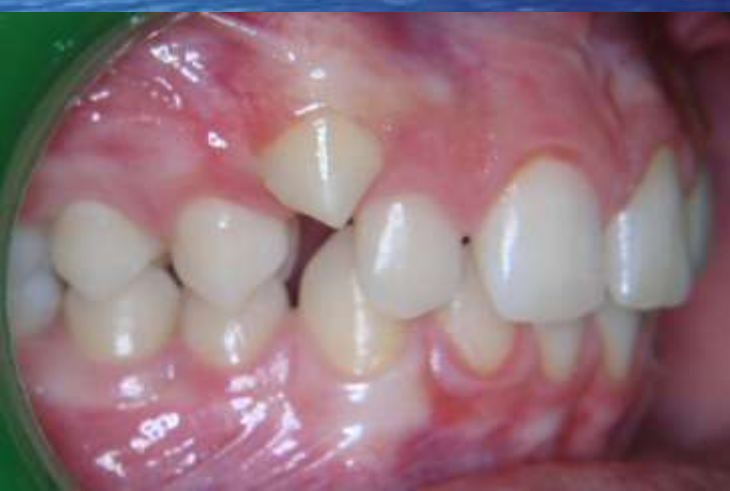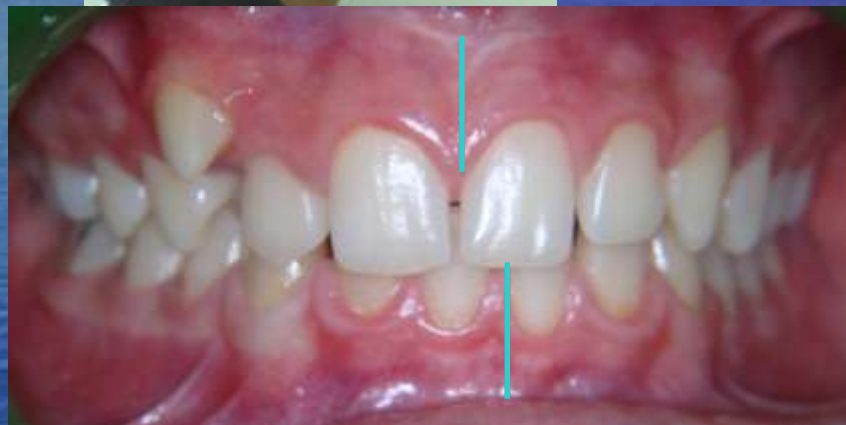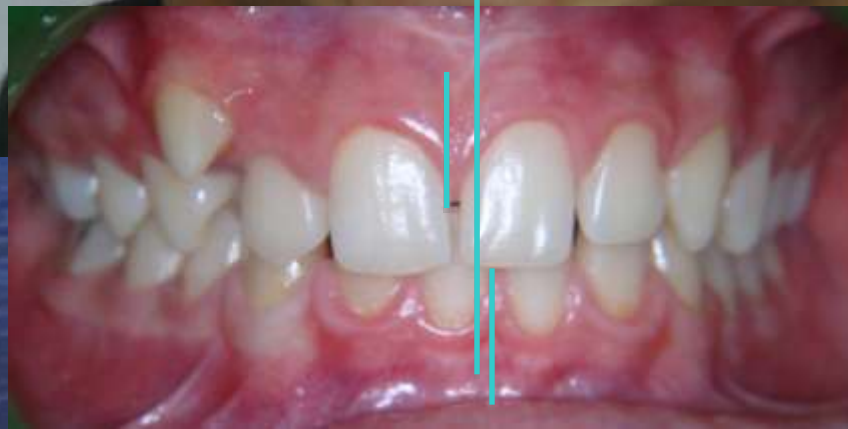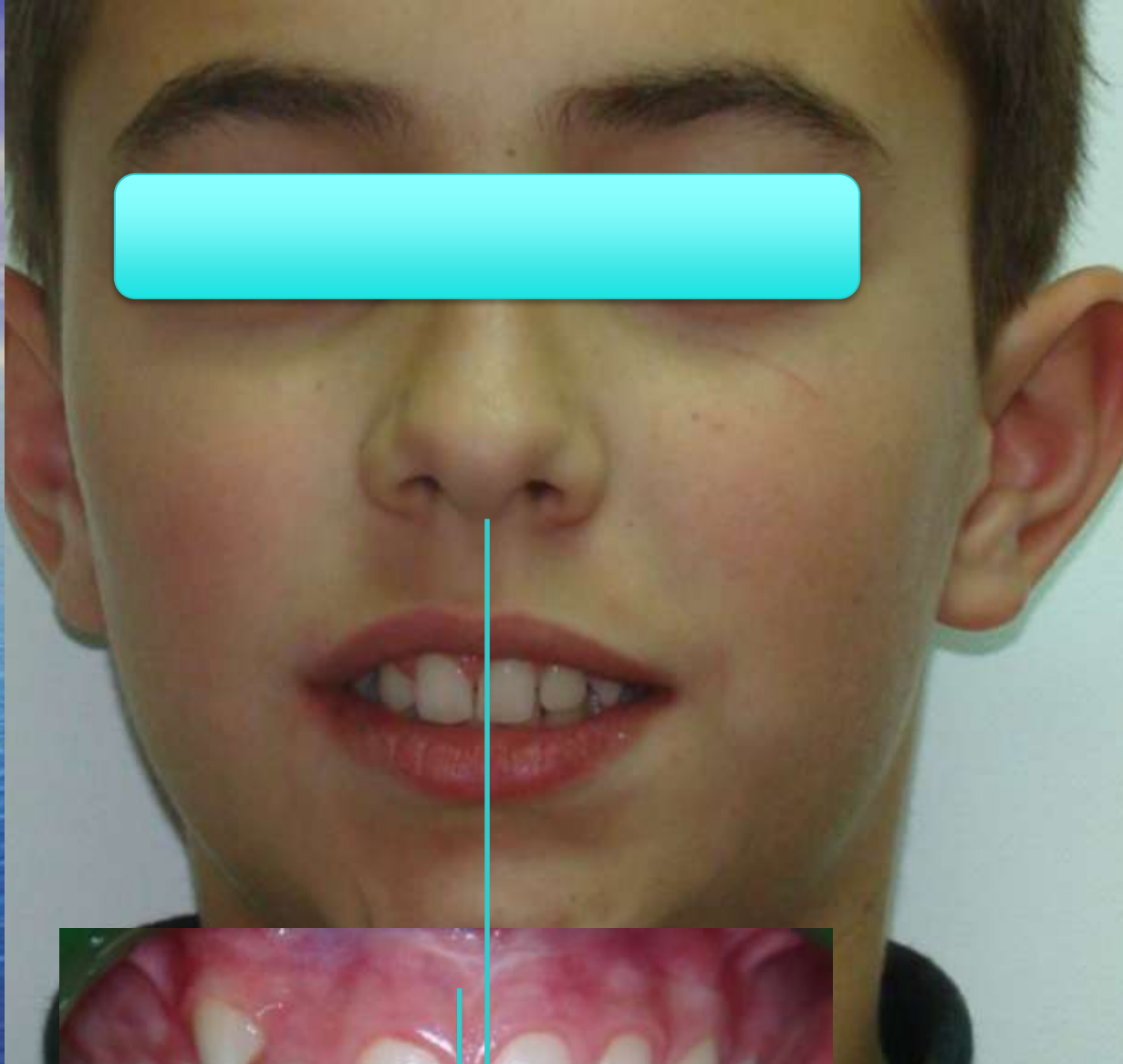


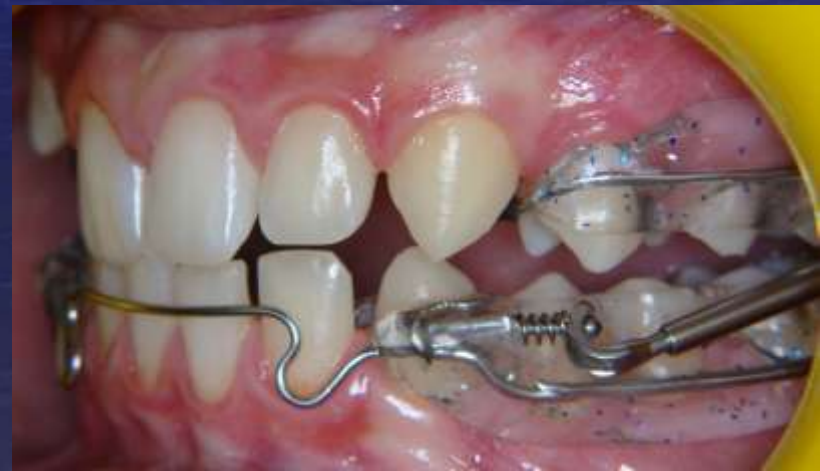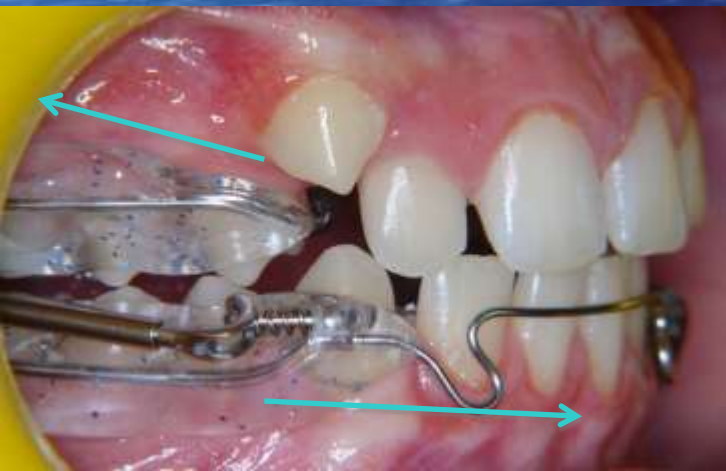
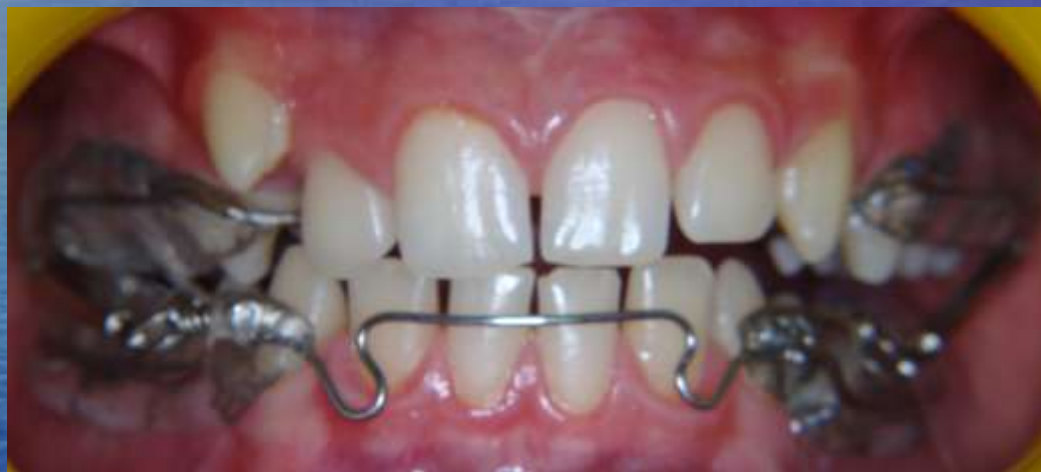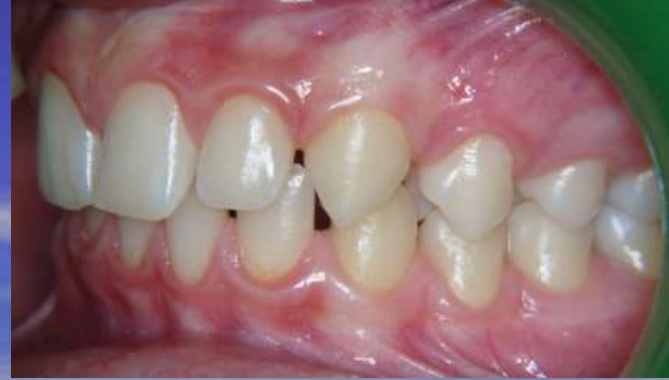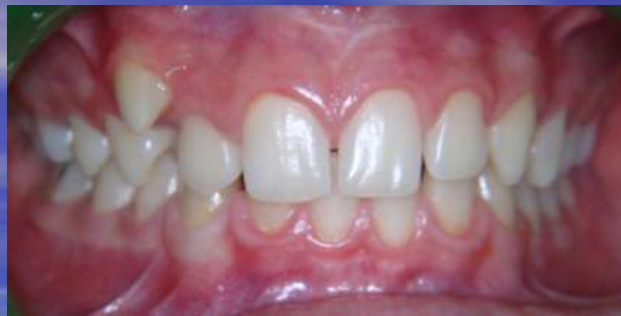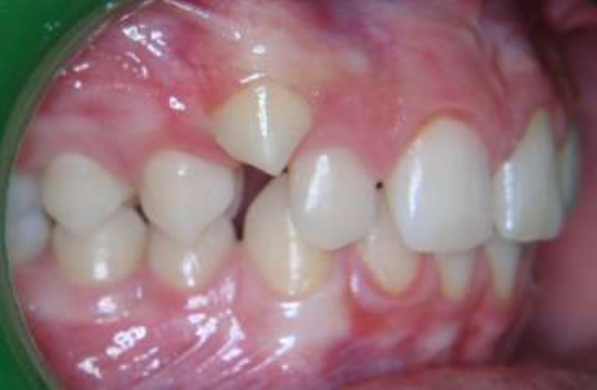Classe II 2 +++

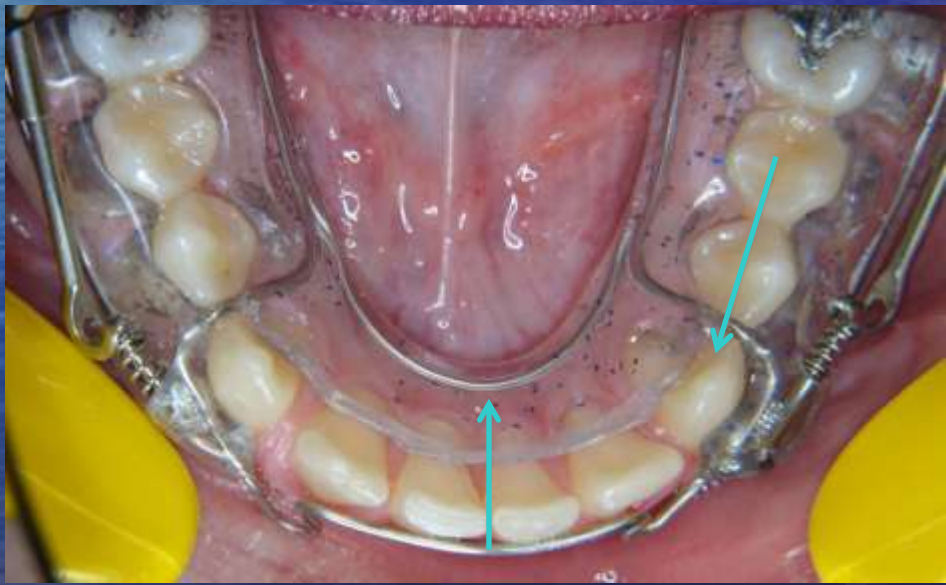
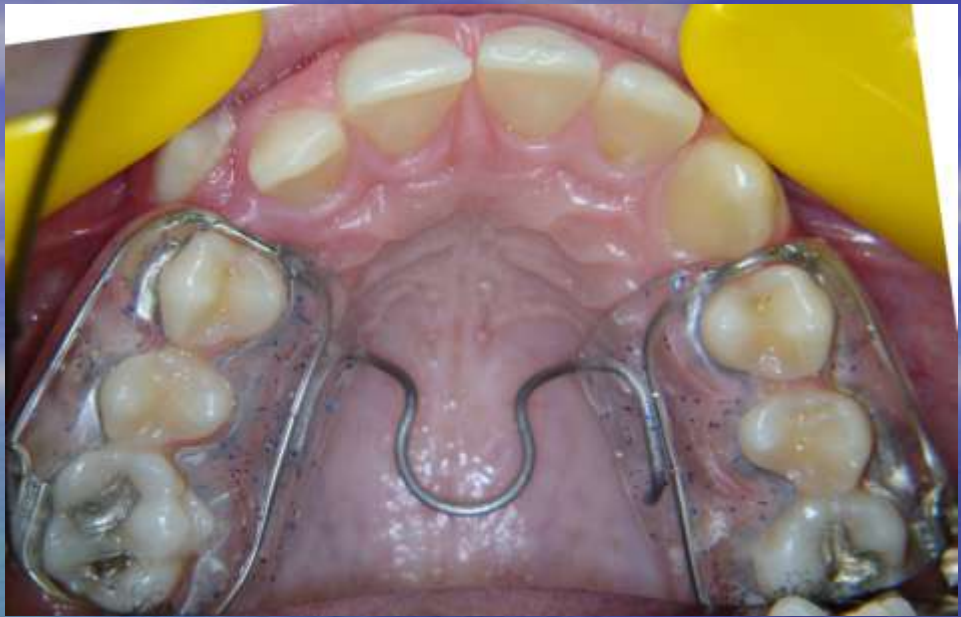

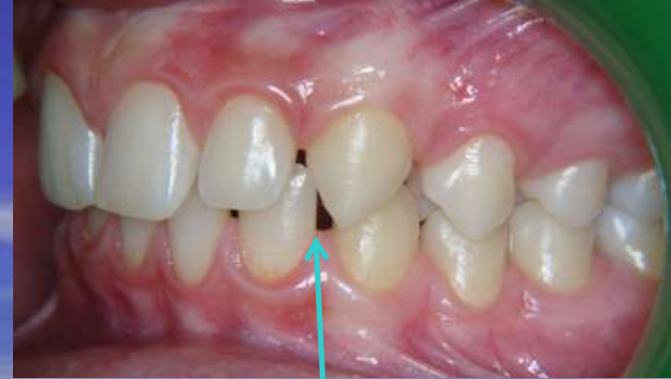C.
13 ans











PUL + 9M





