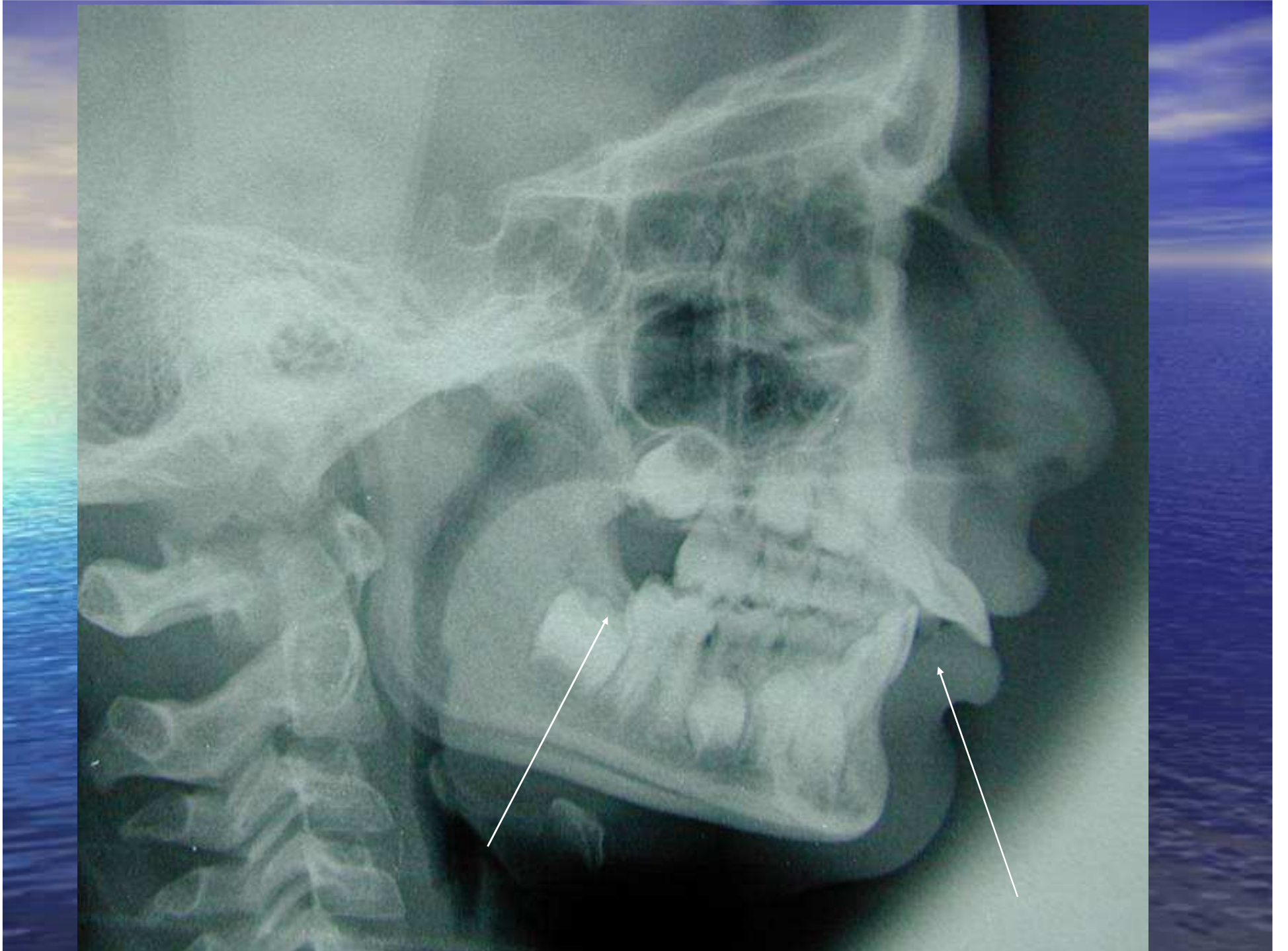
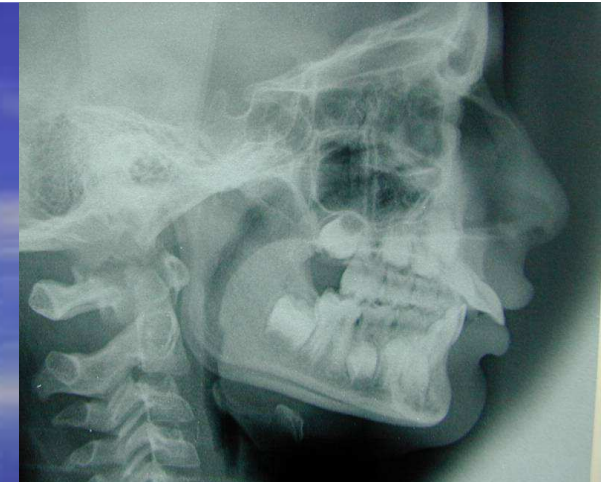
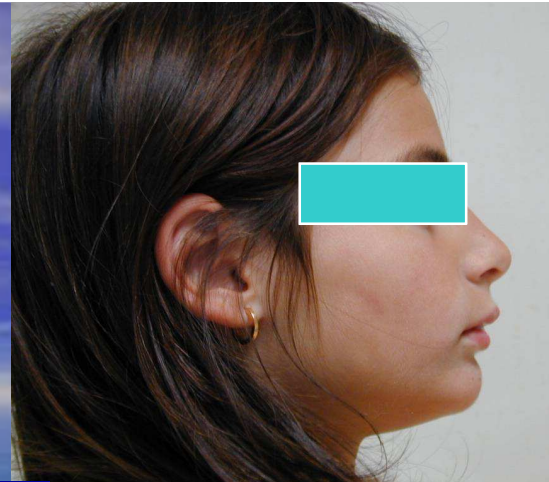



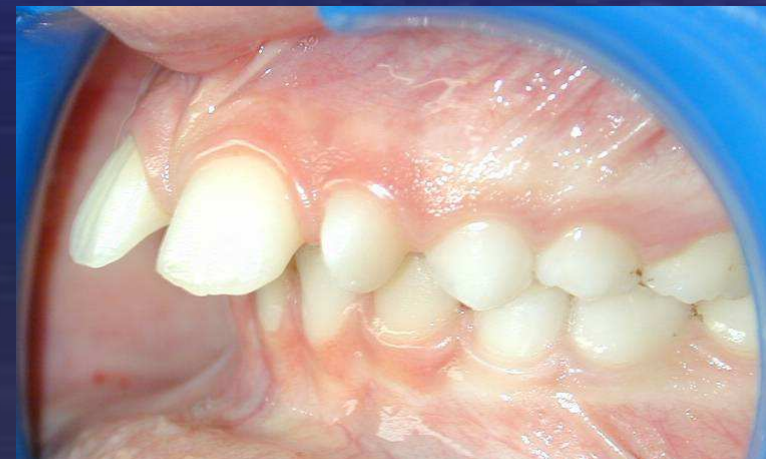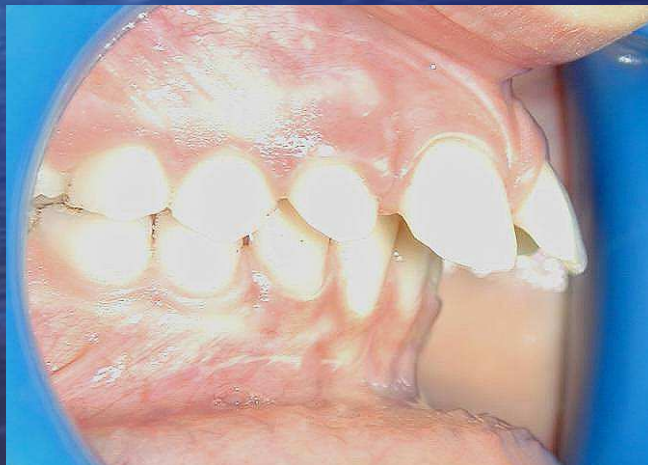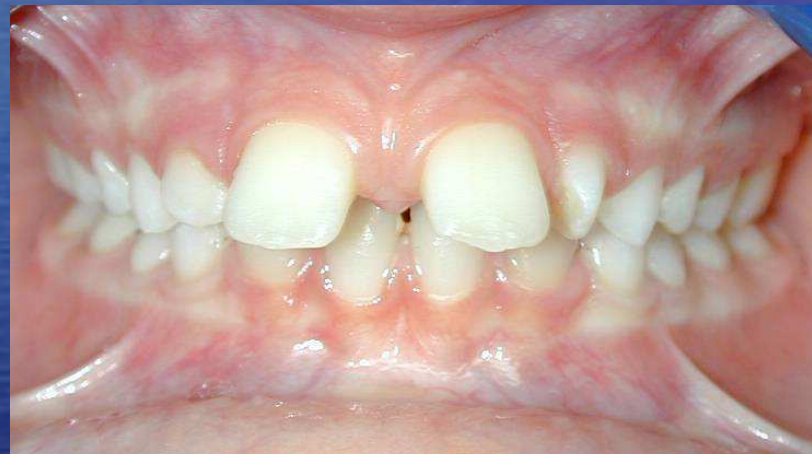Interception Classe II 1 brachy

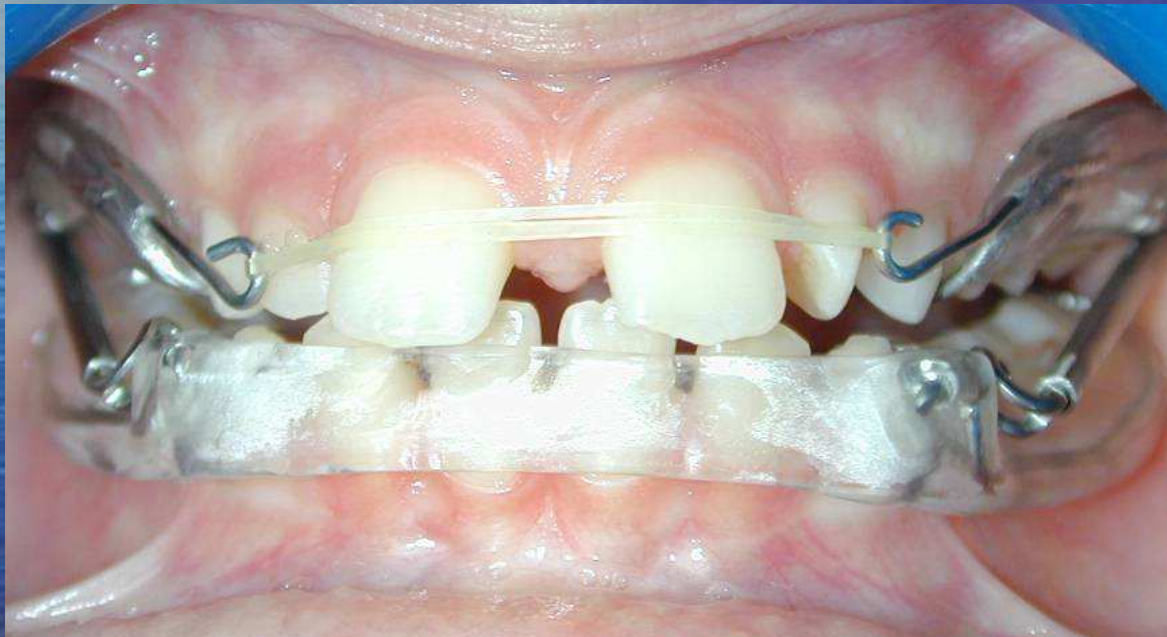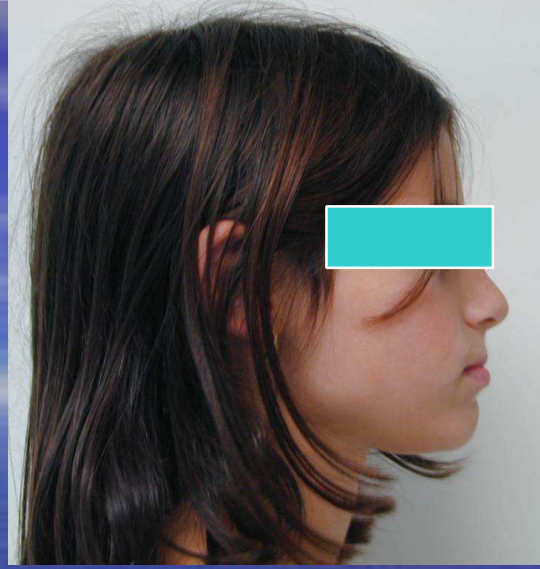



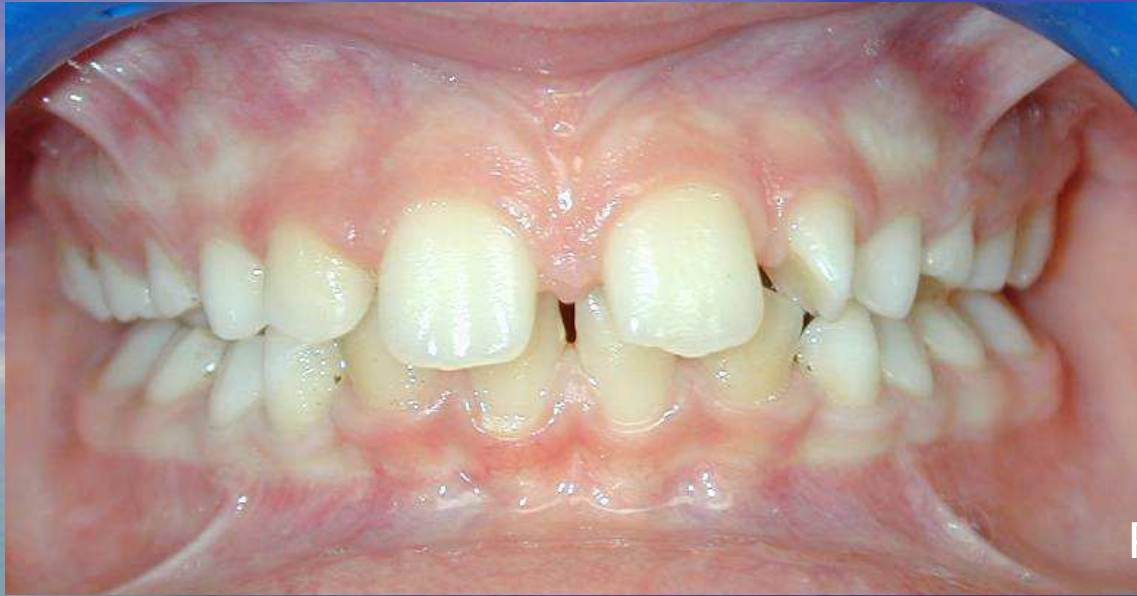
6359 M. 8 ans

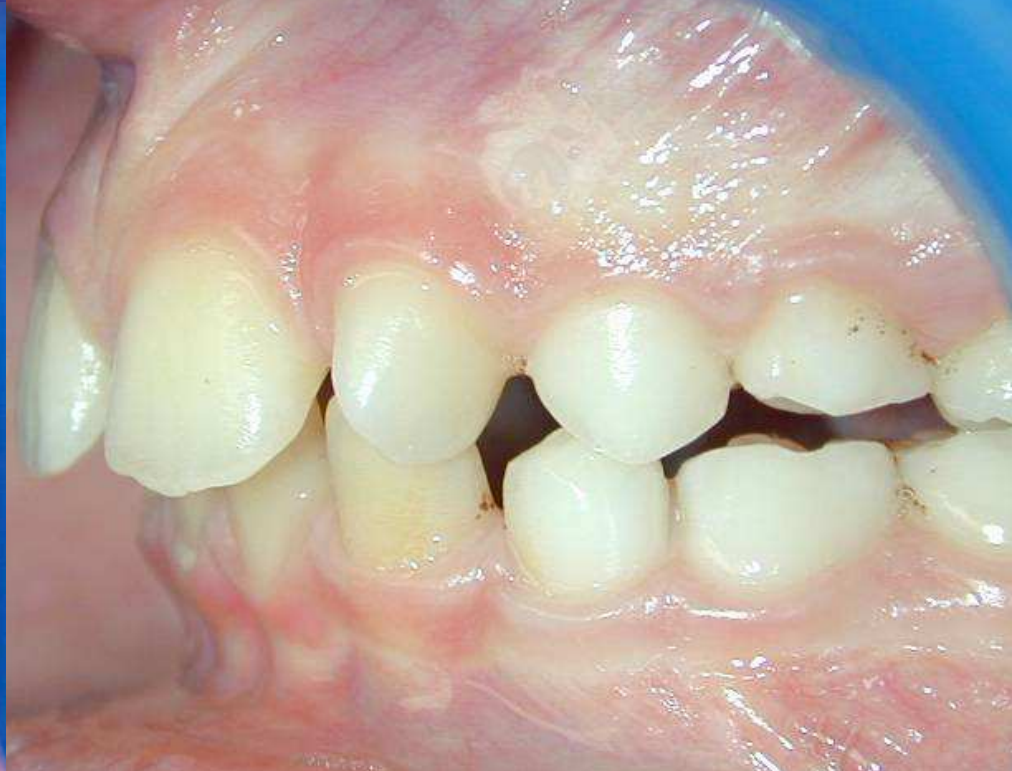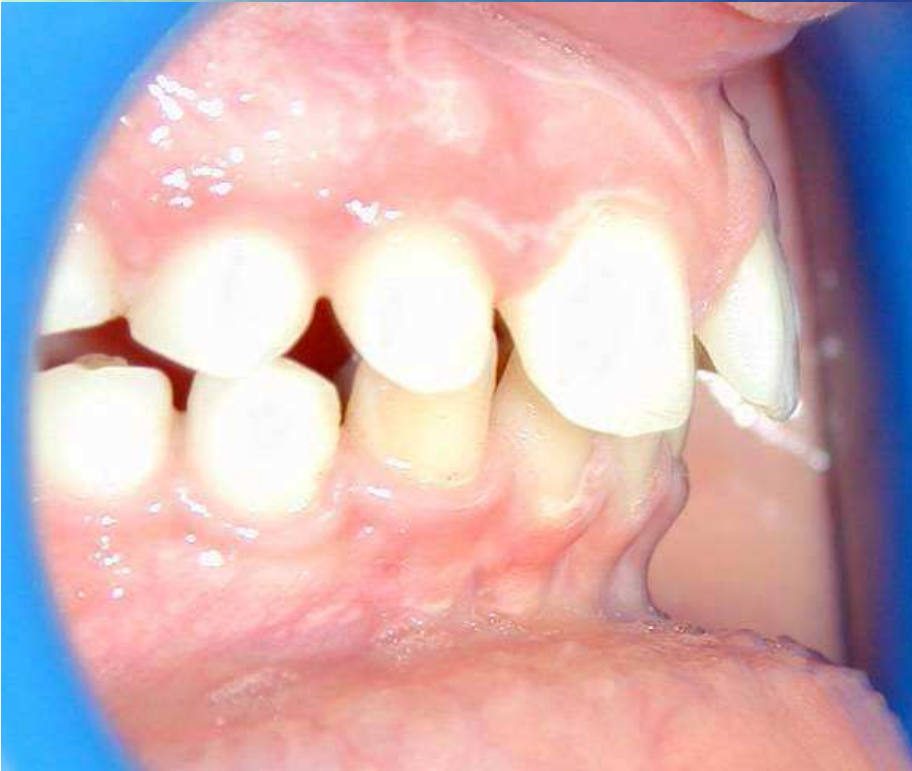Pas de pouce ni autre

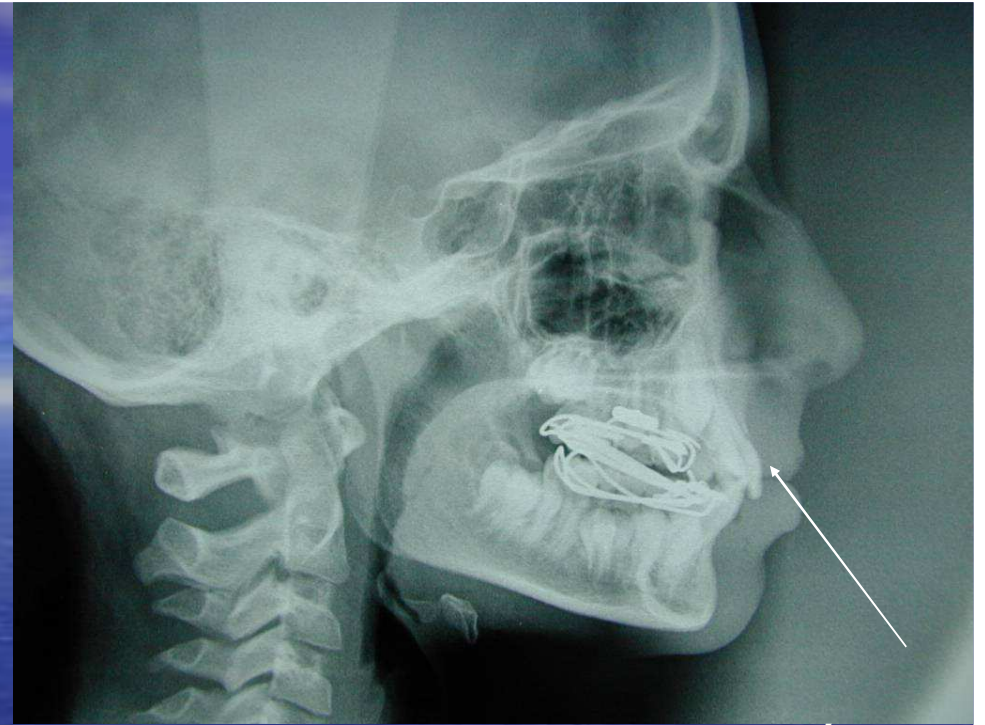
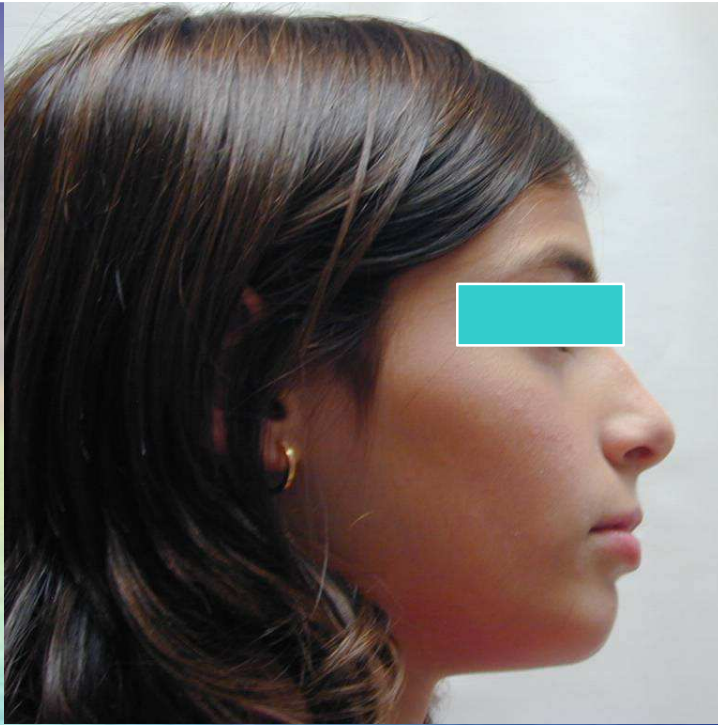




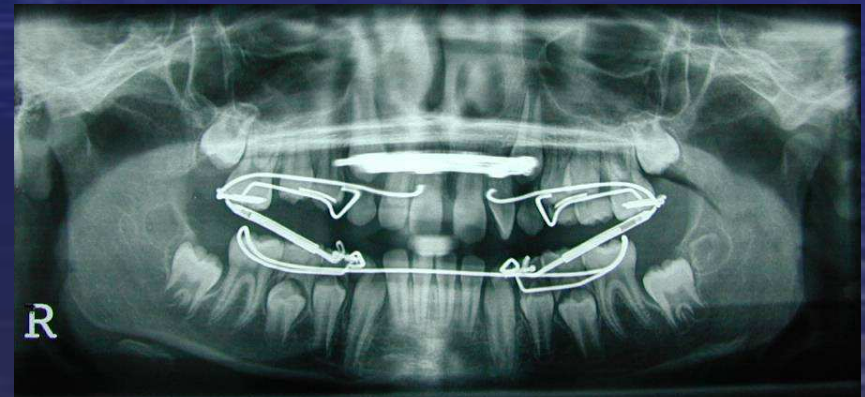
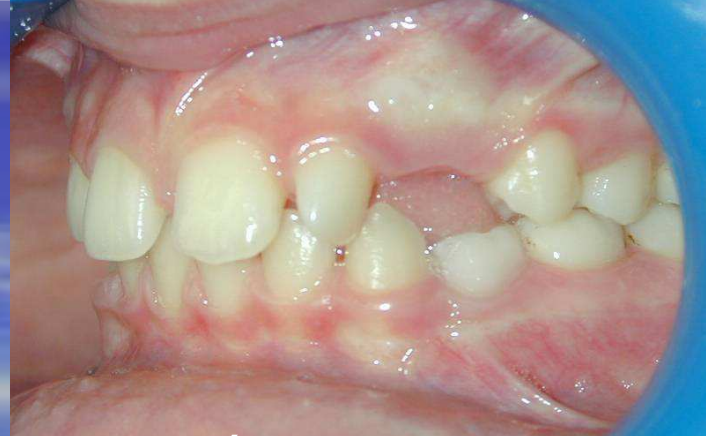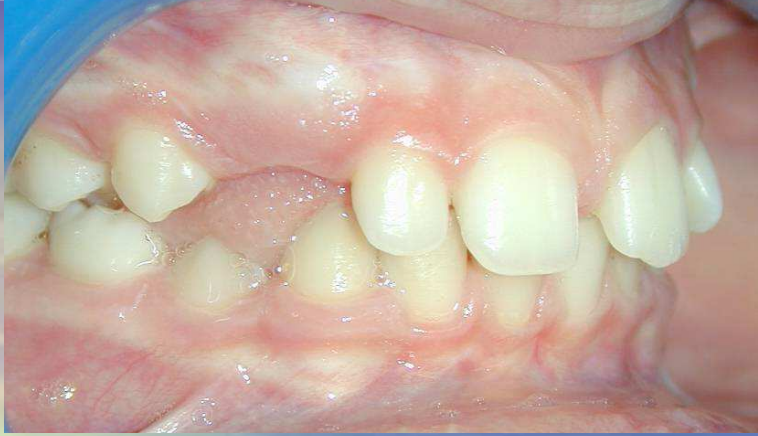PUL+6mois



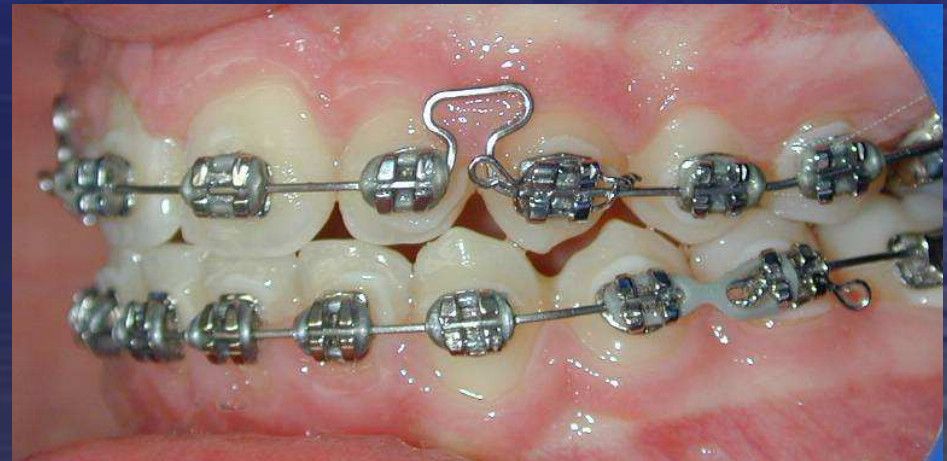
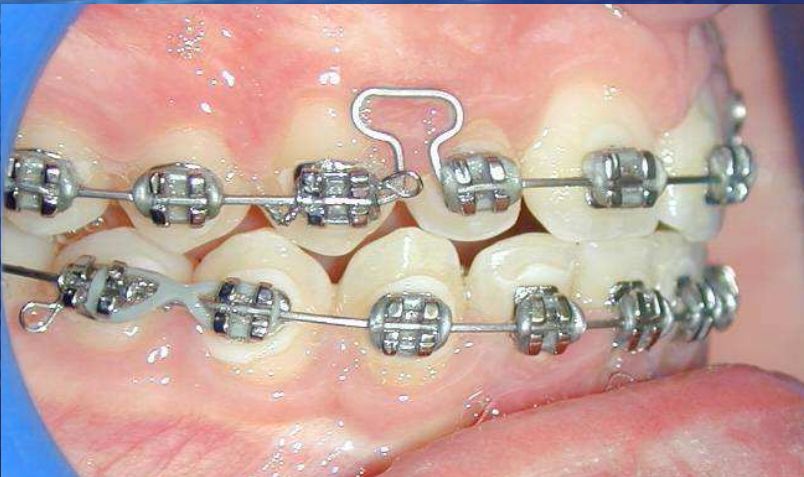
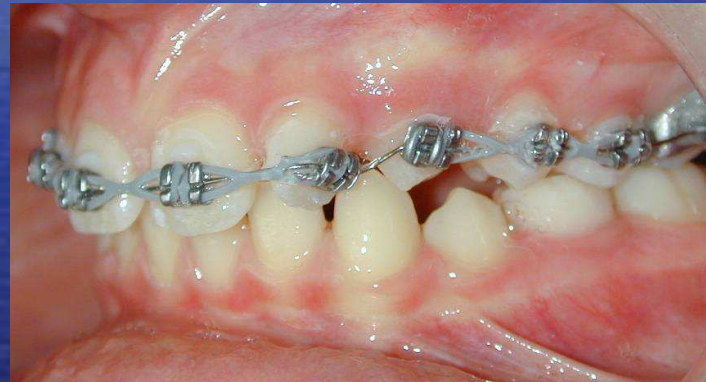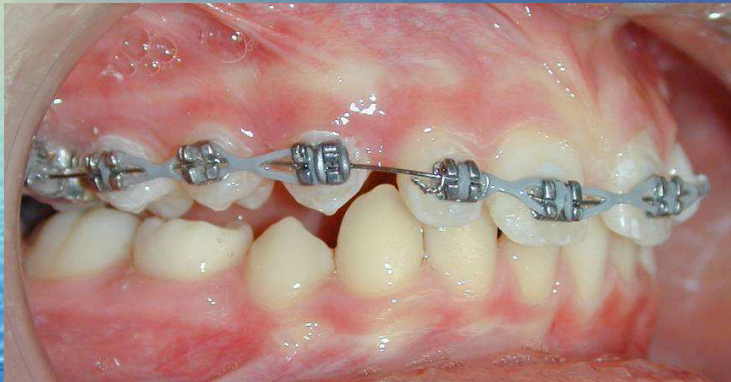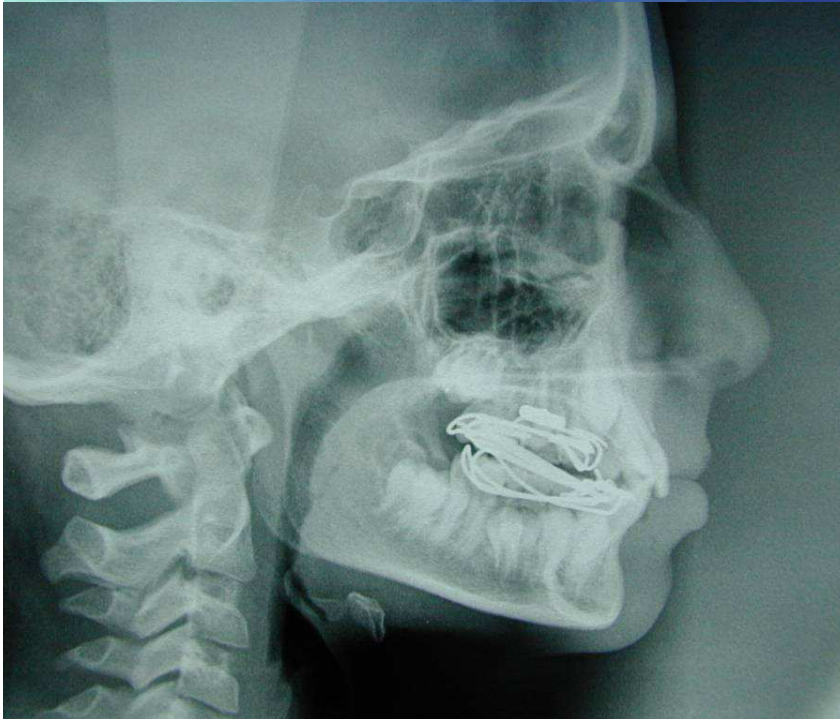
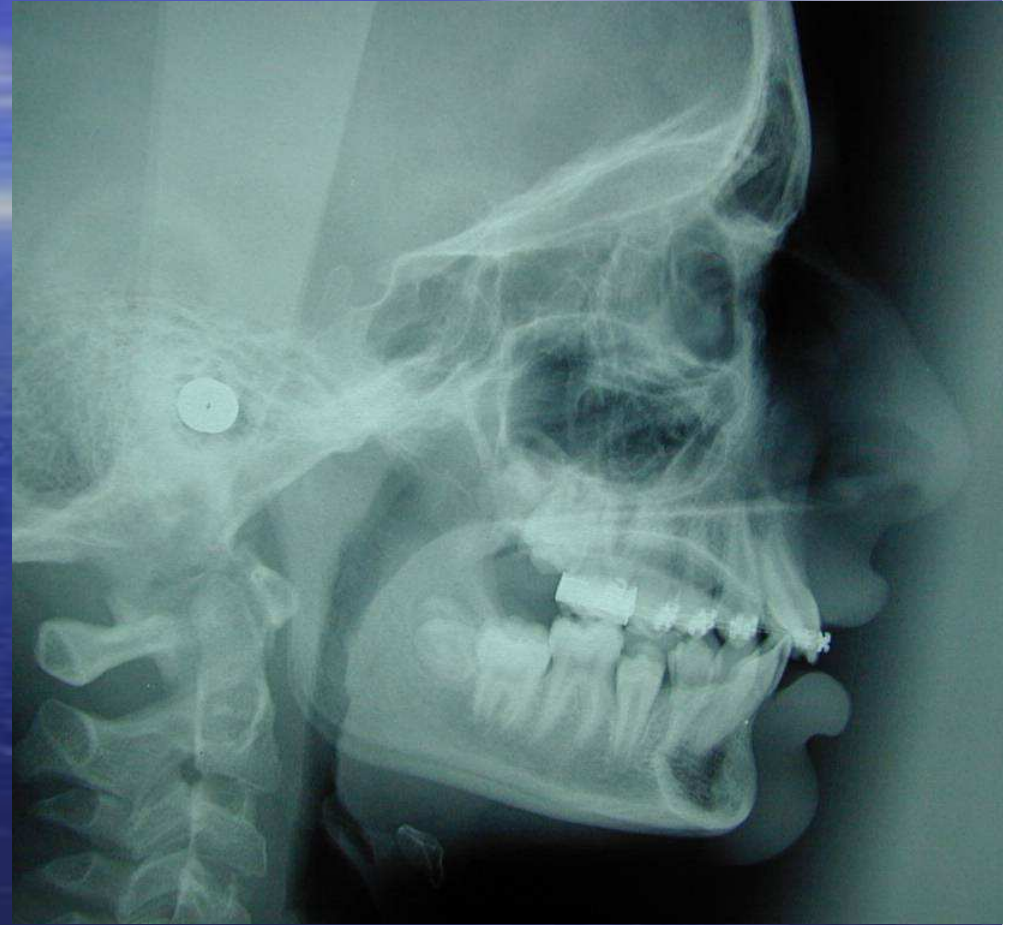
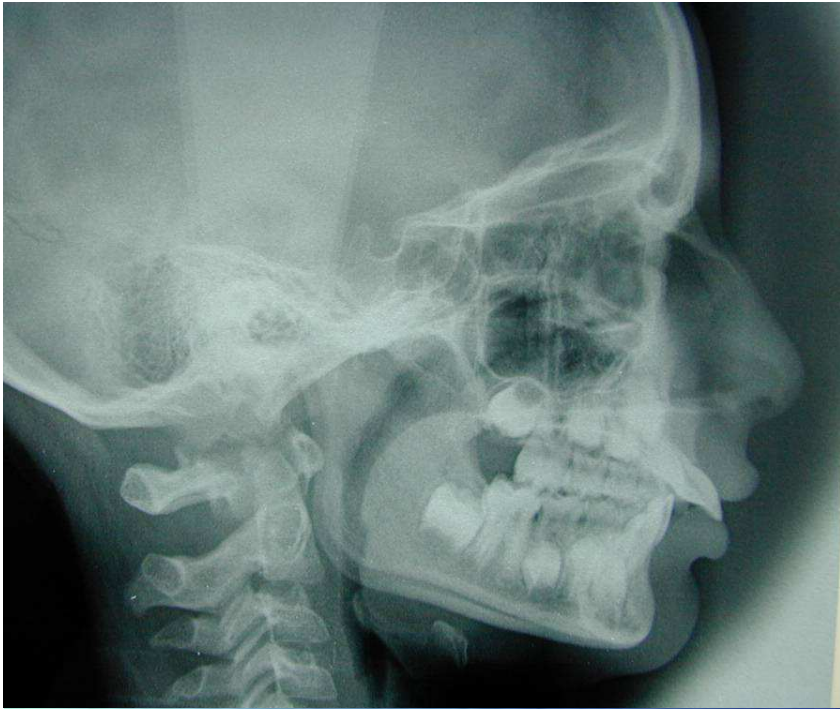
BV coupé

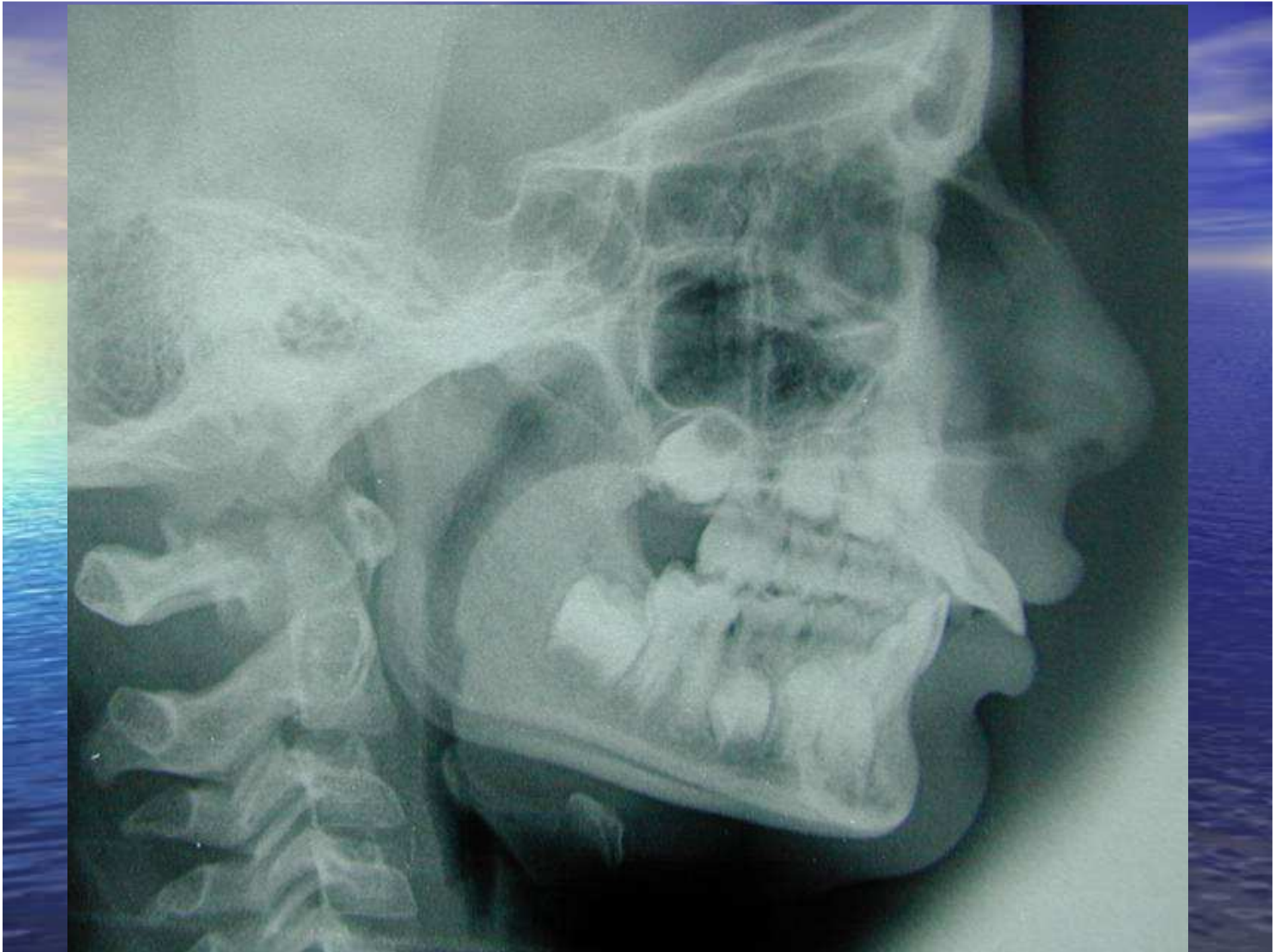


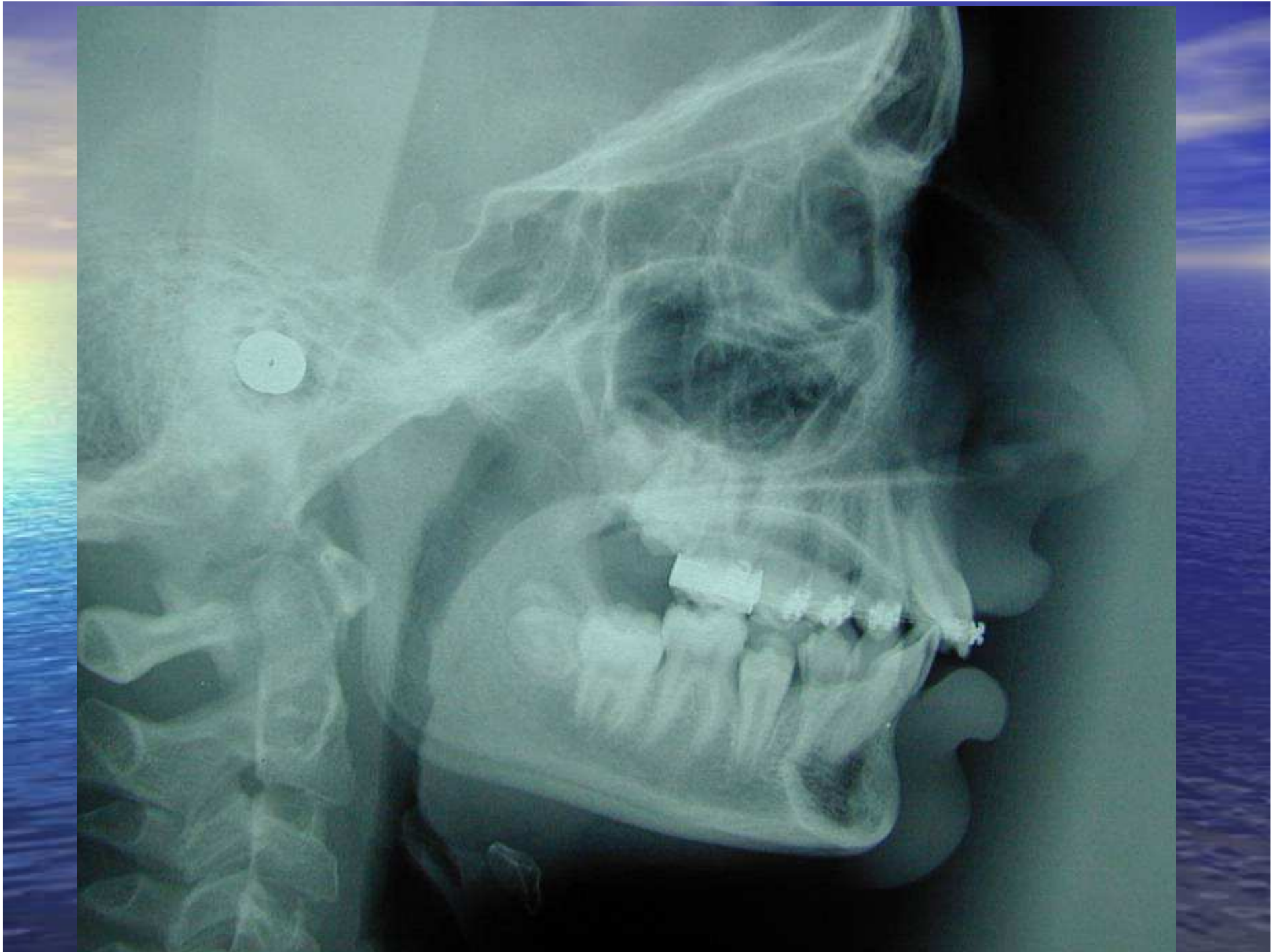

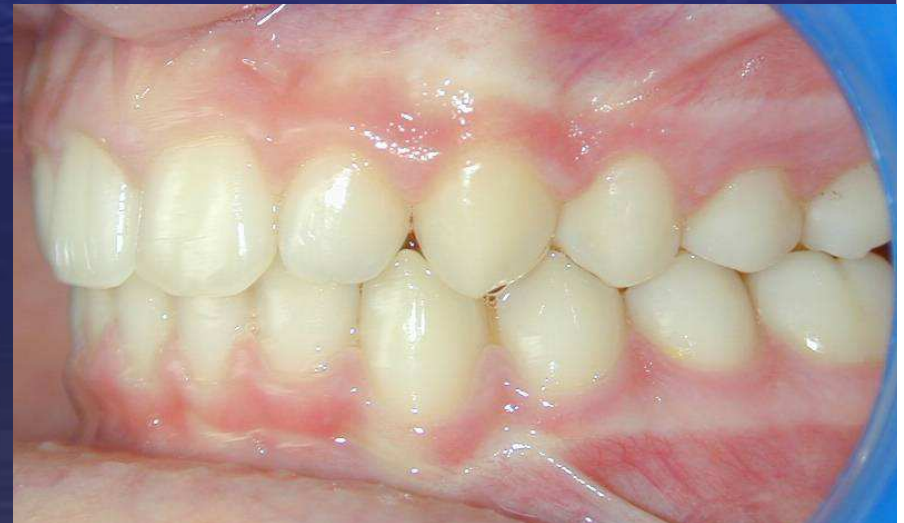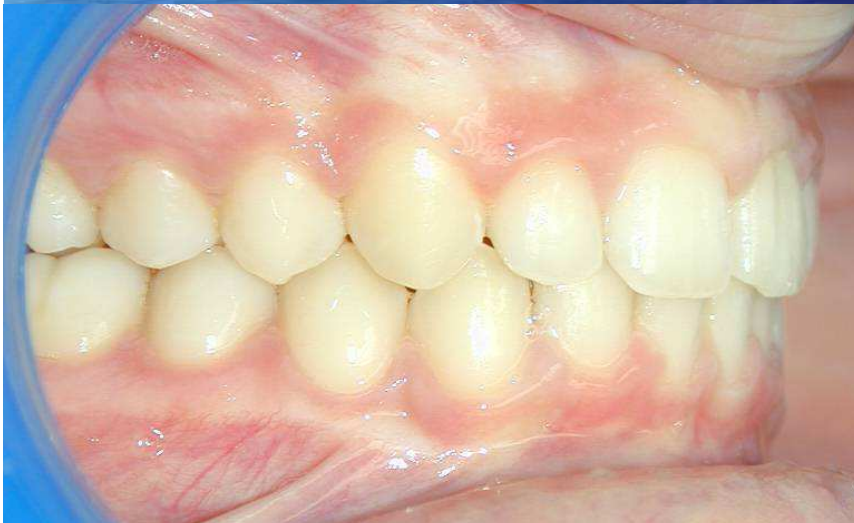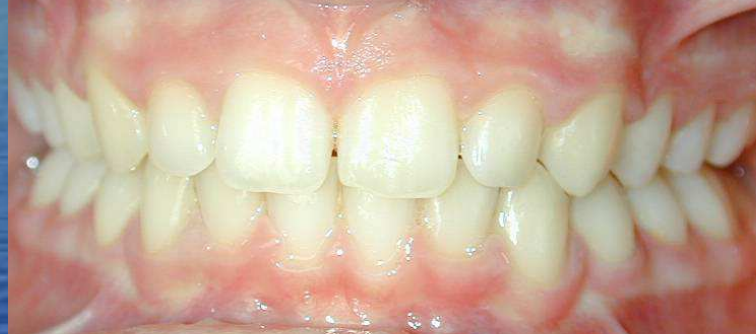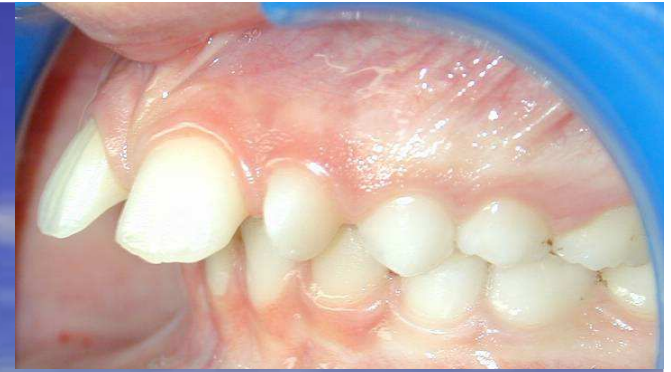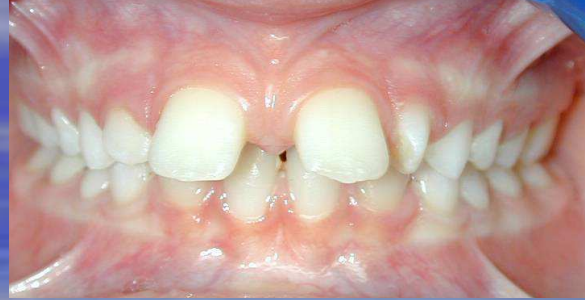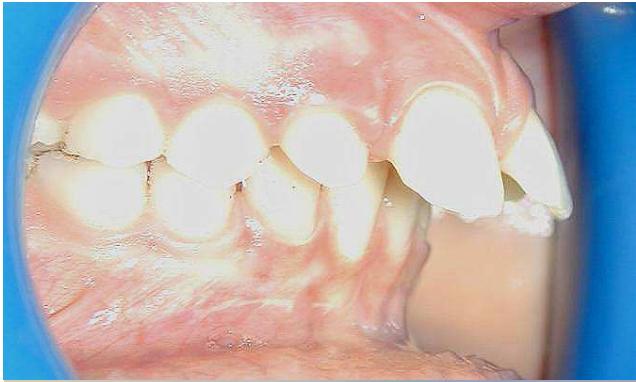Classe 1+ denture définitive = début du fixe

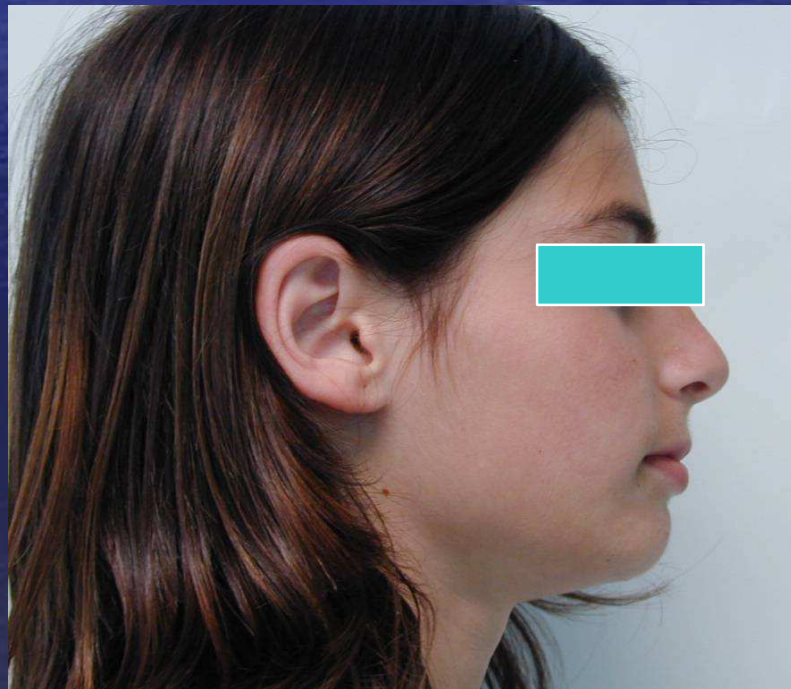
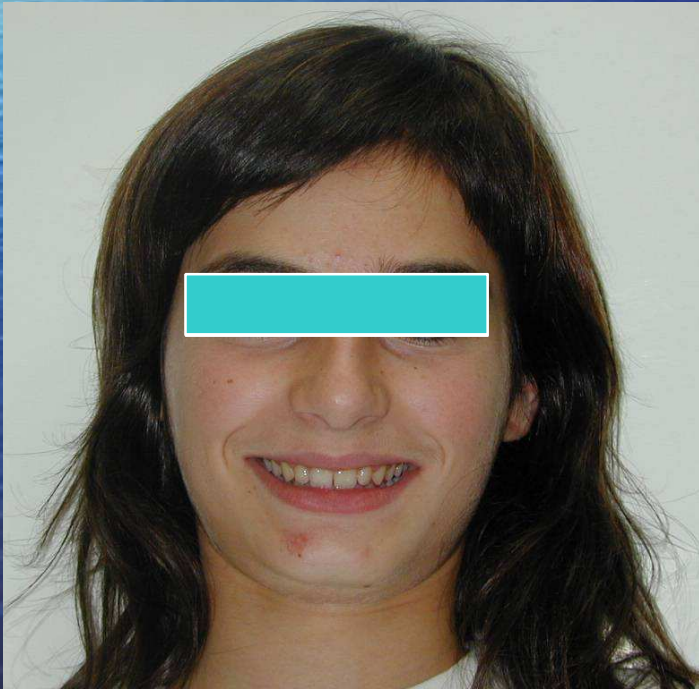
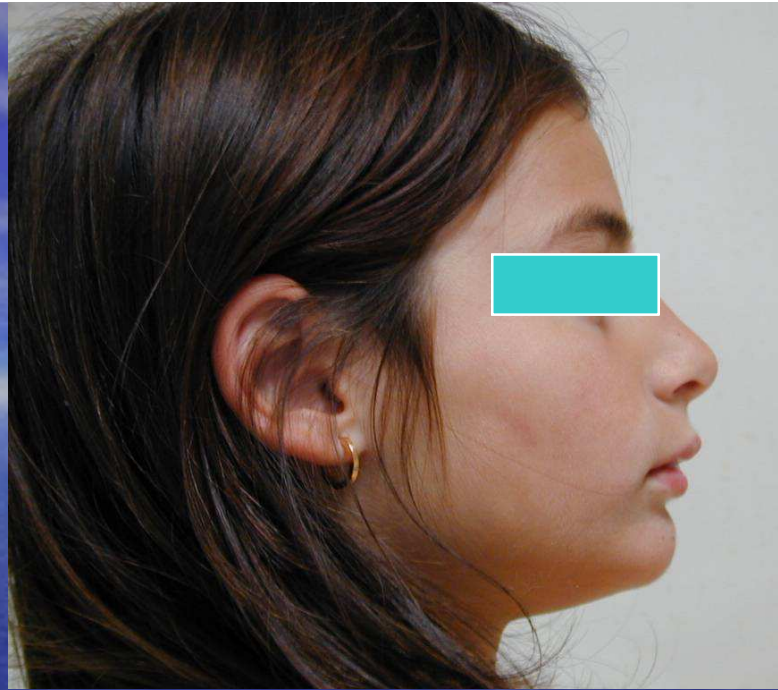
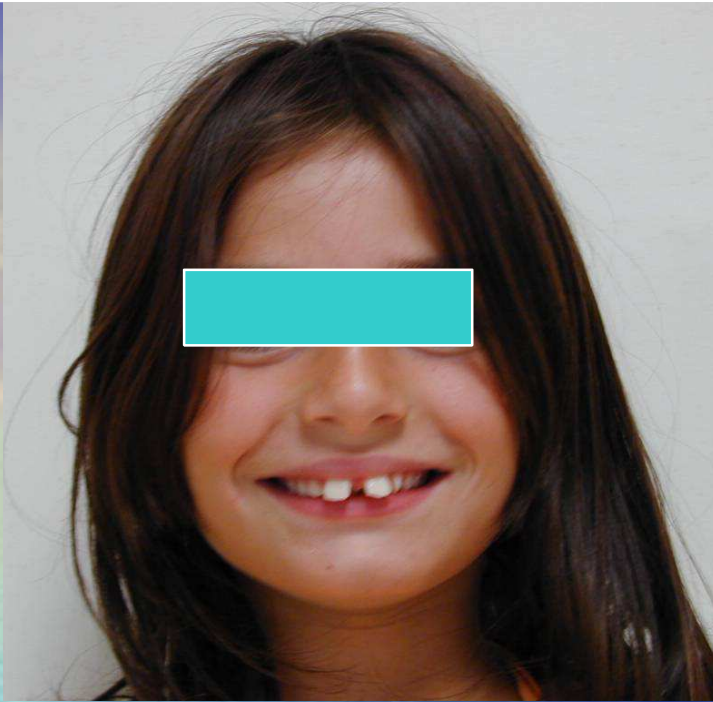








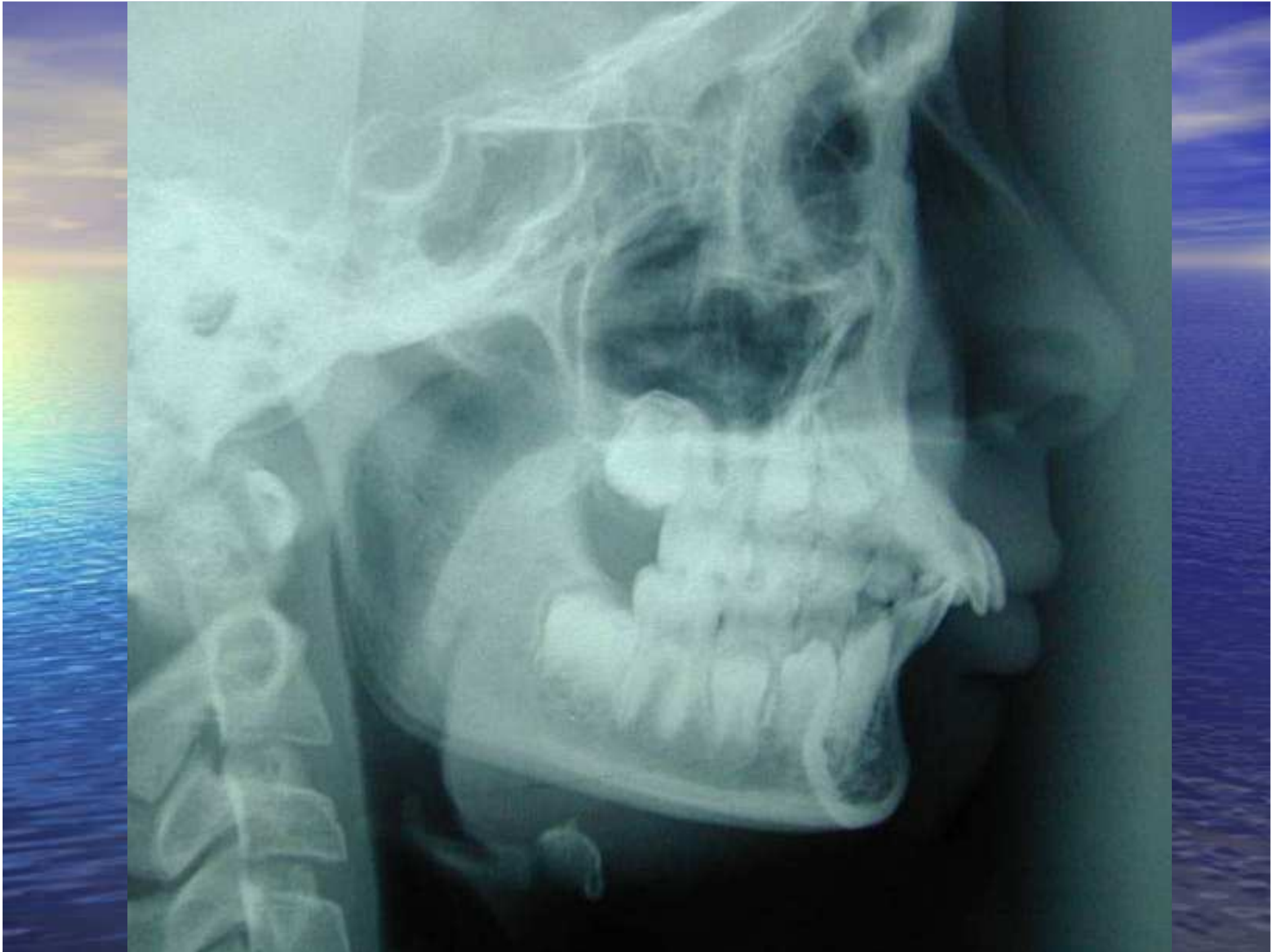


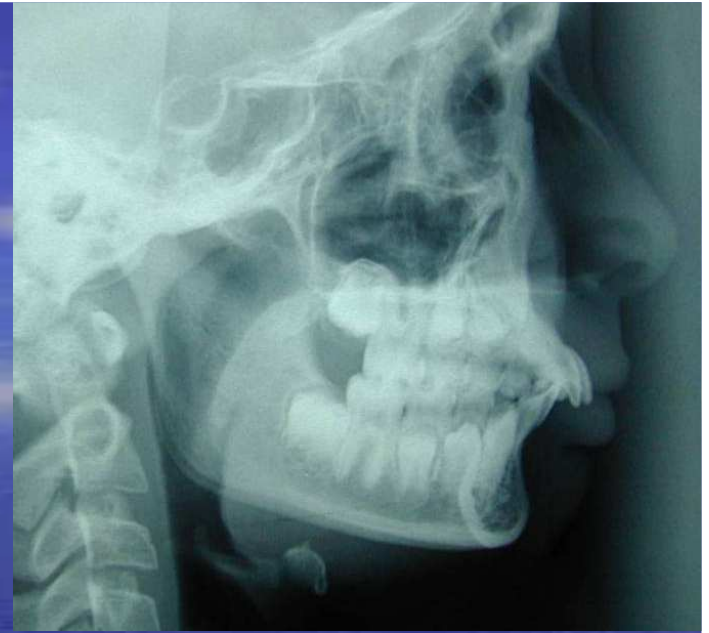
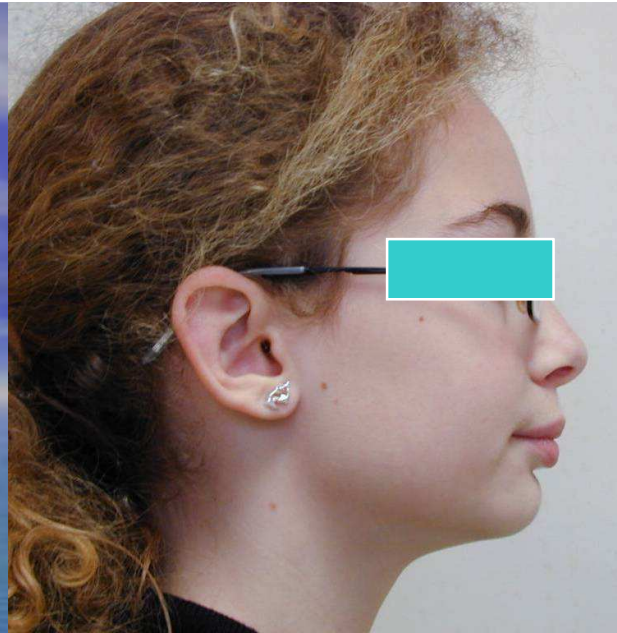
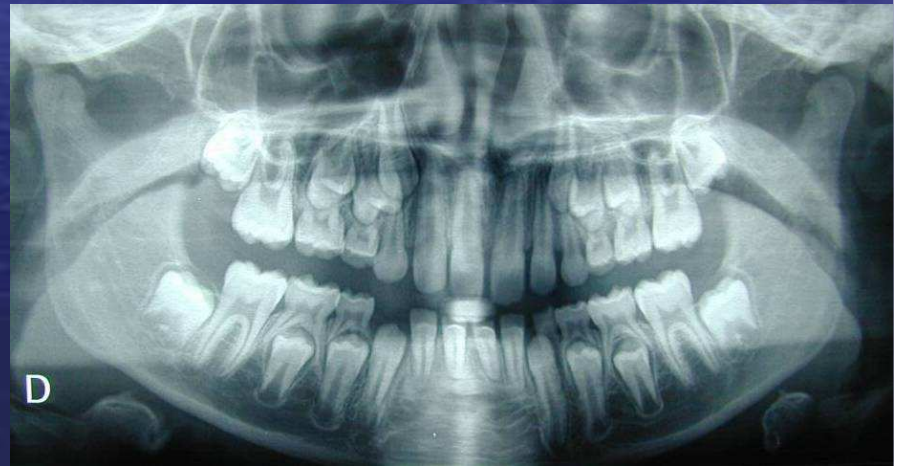
Classe II 1 hypodivergent++

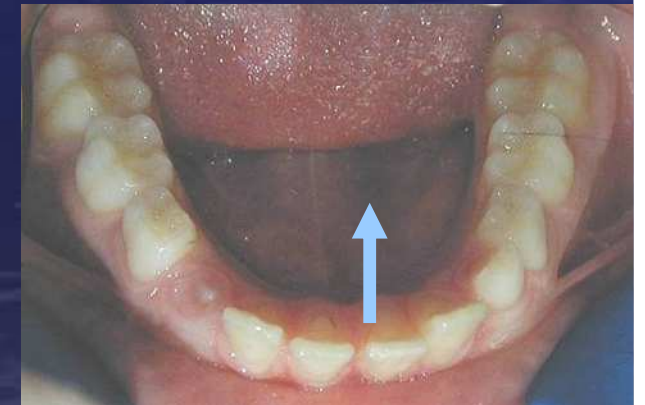
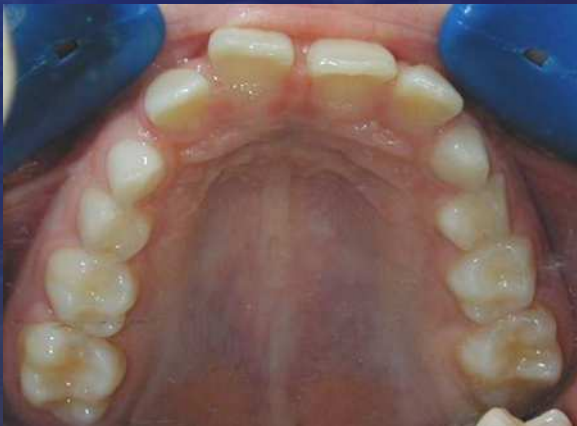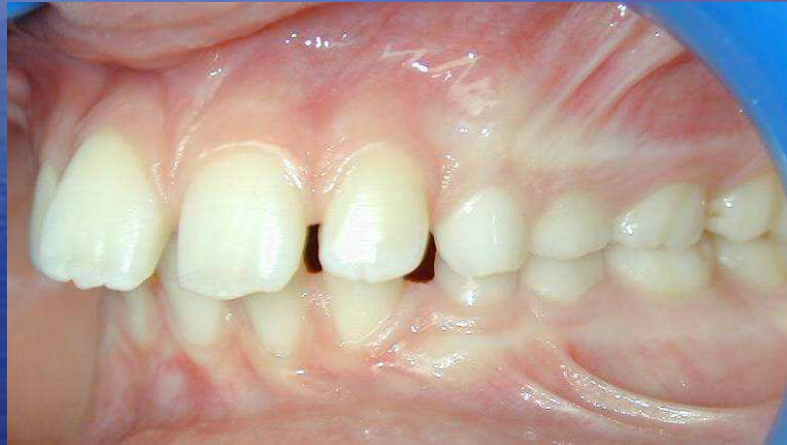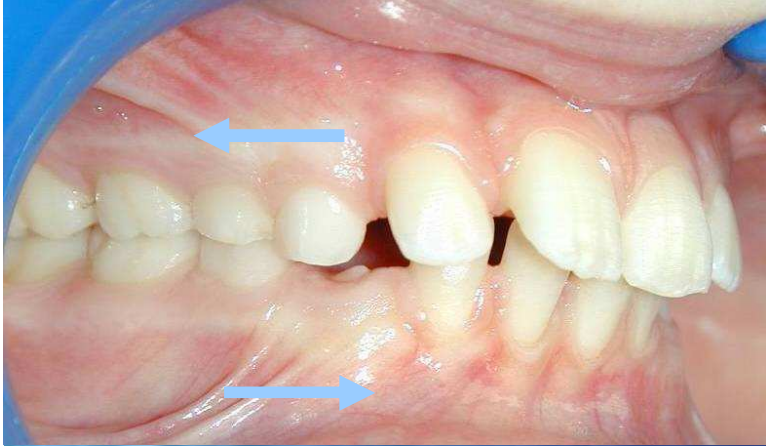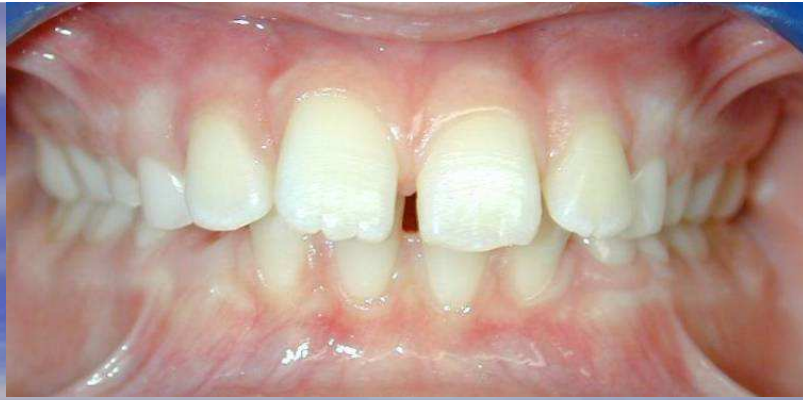Biproalvéolie +++

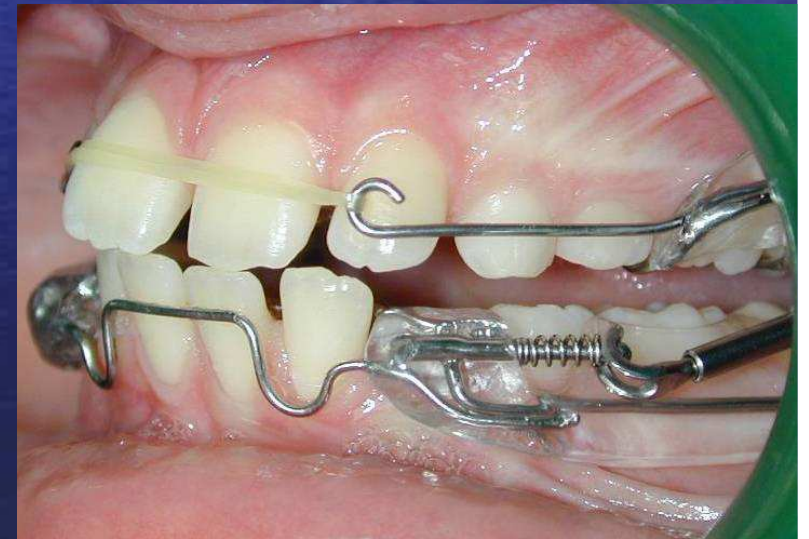
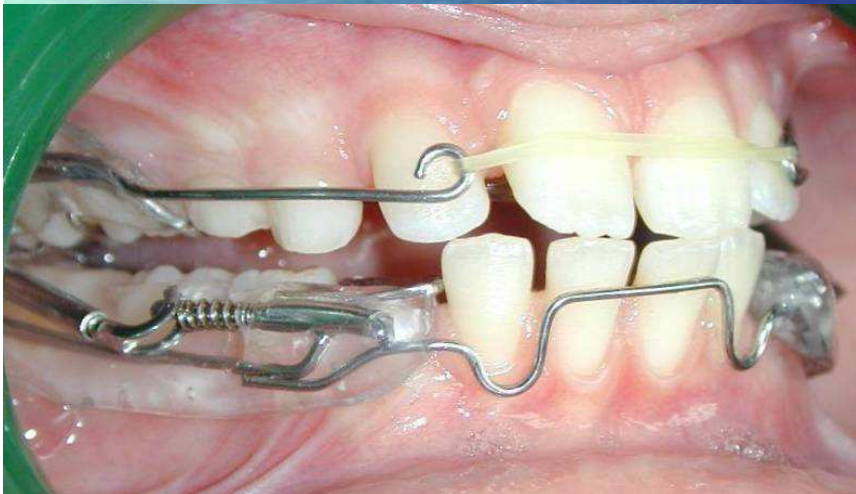
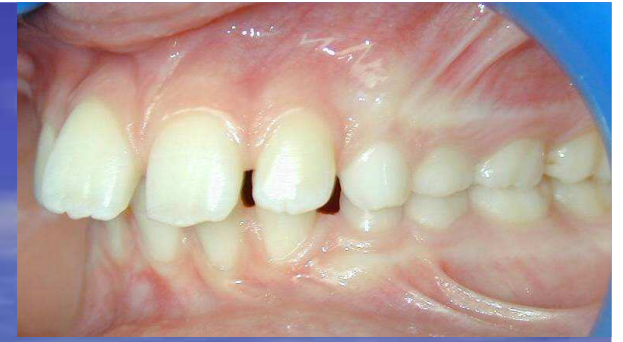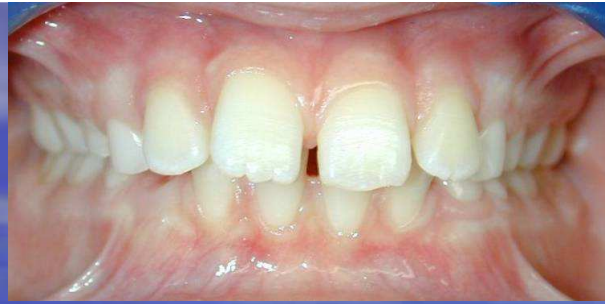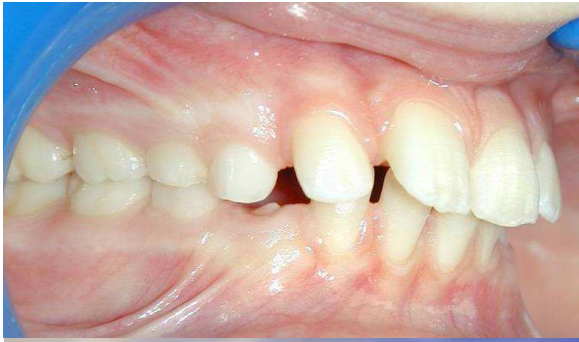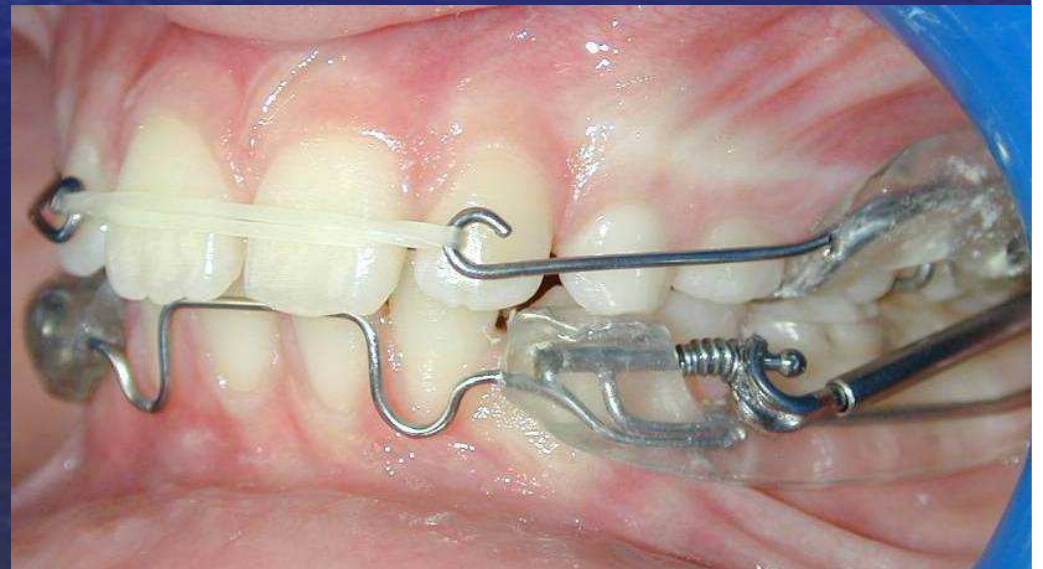


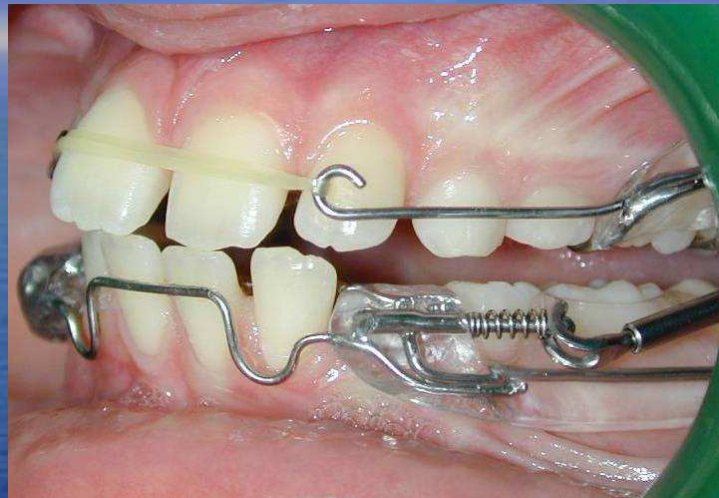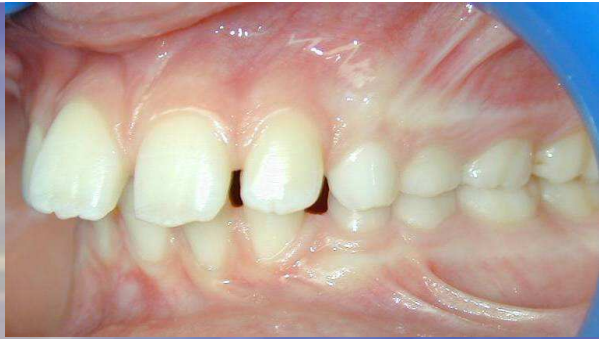S P. 11 ans (04/2006)

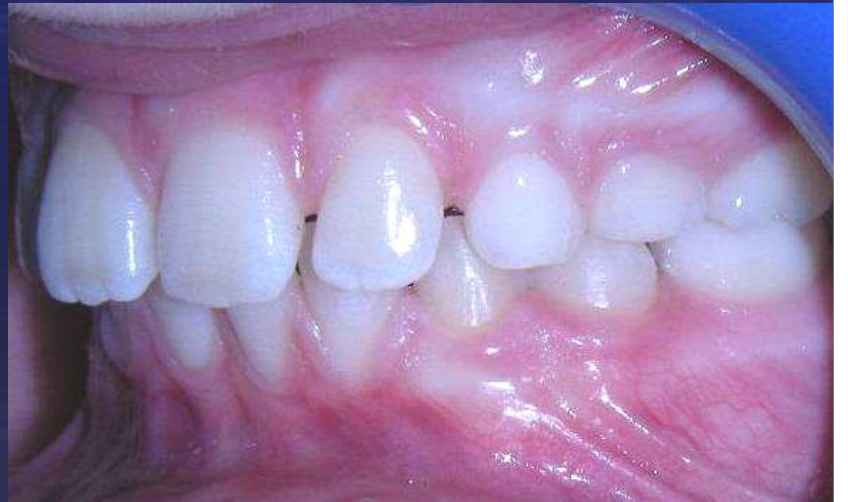
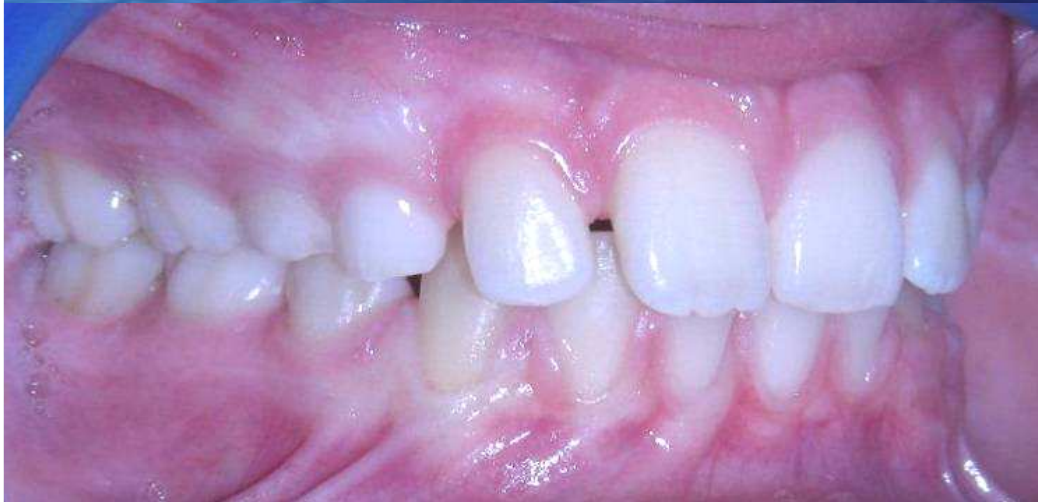
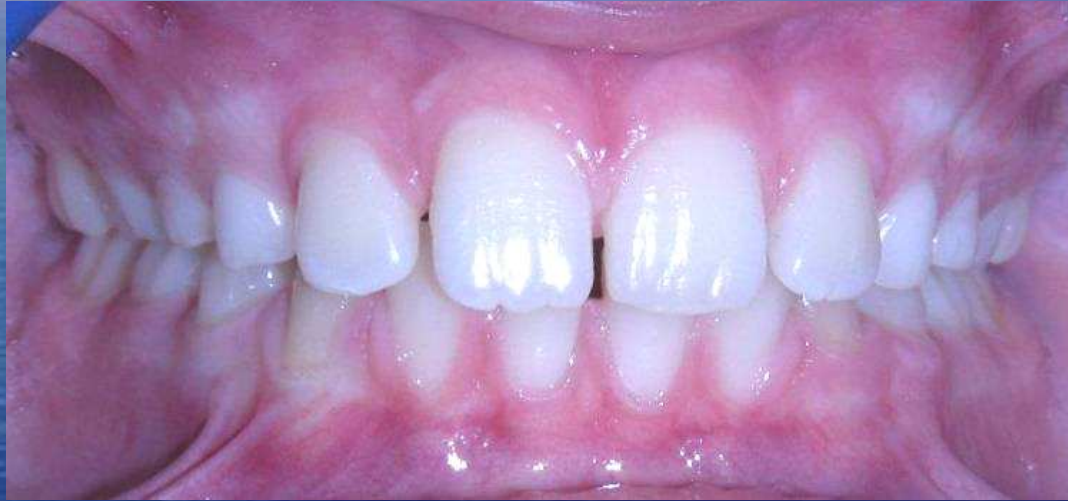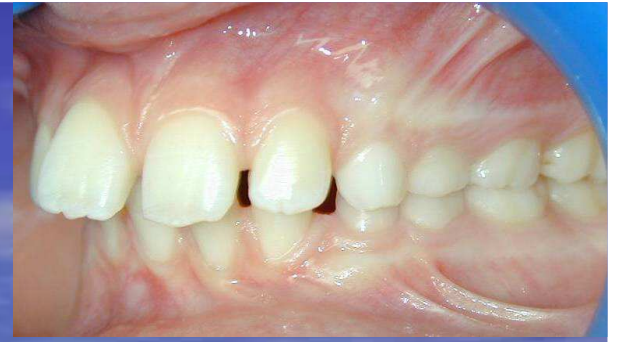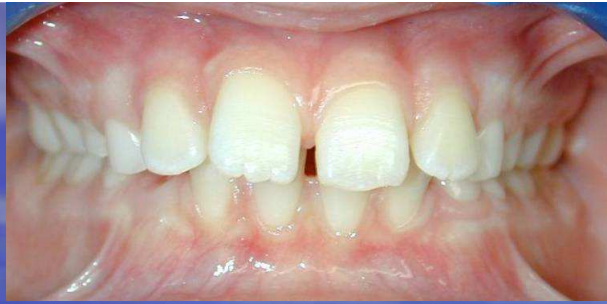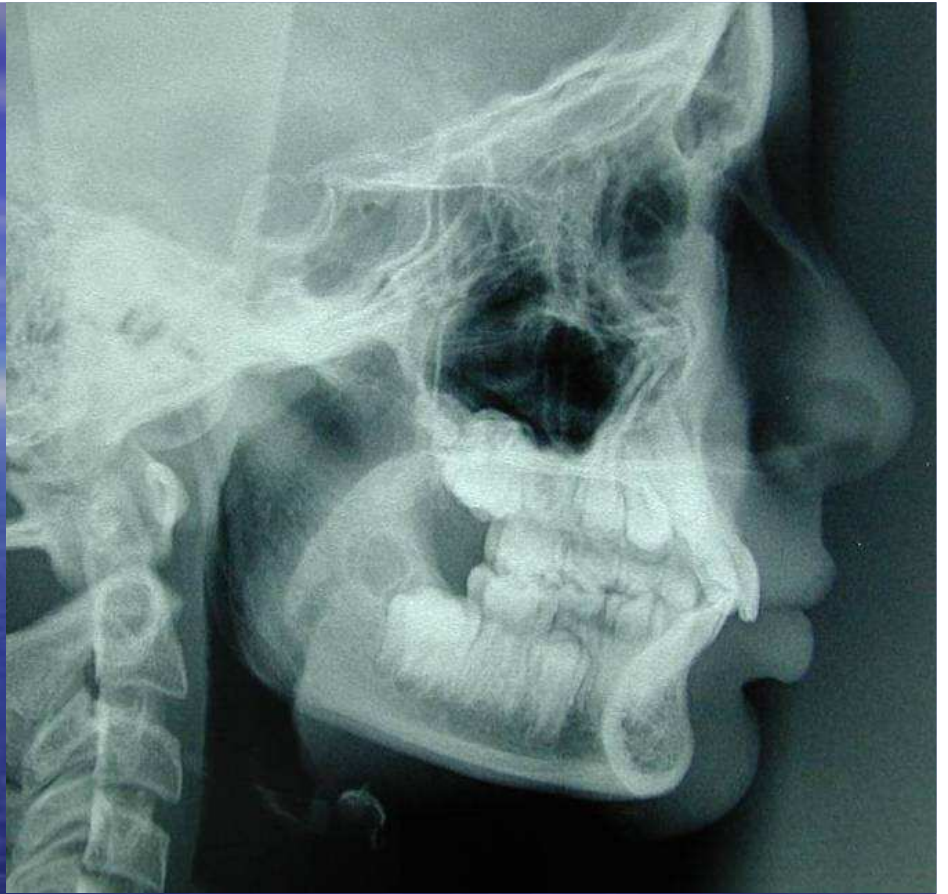






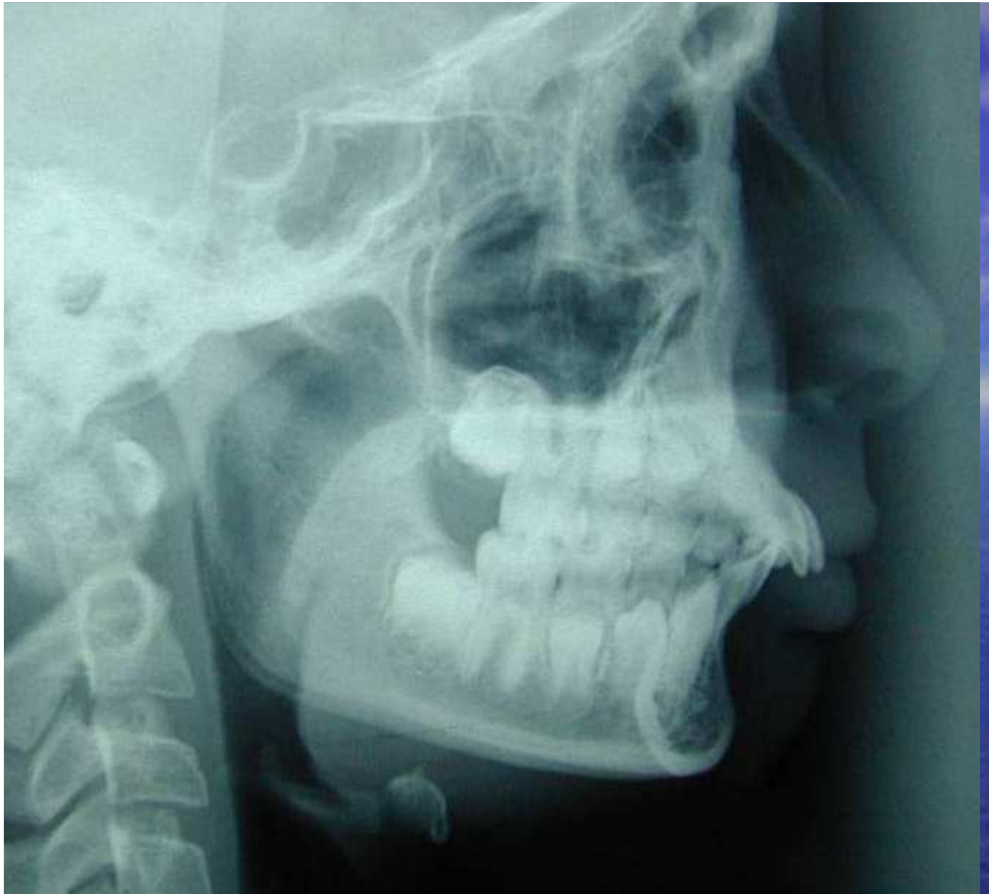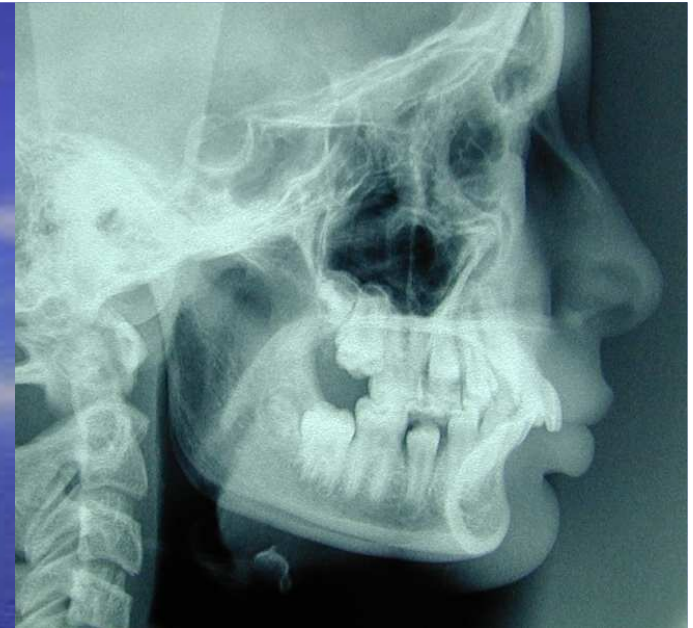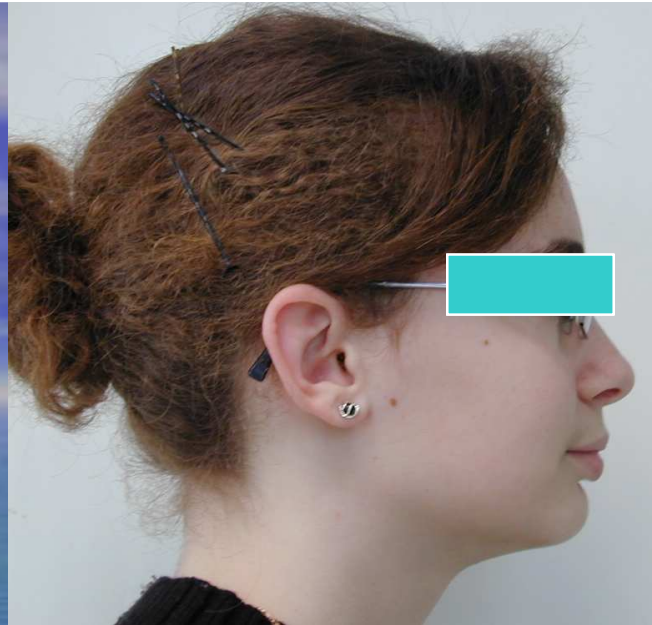PUL + 3 M

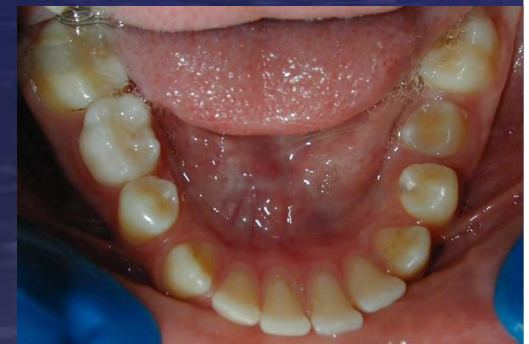
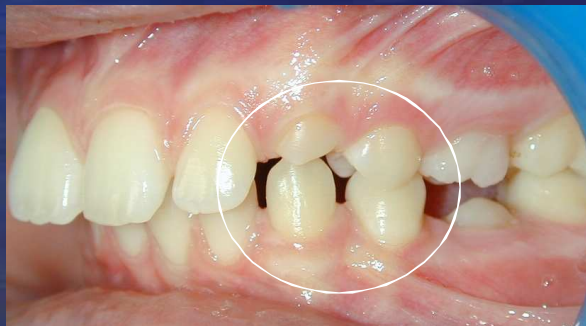
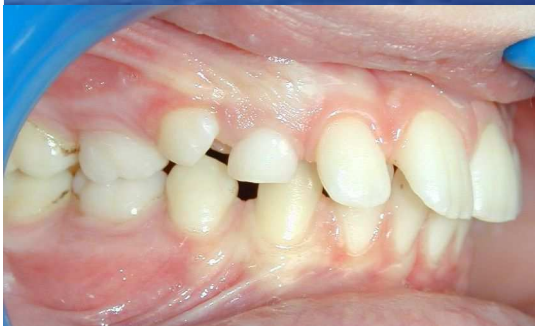
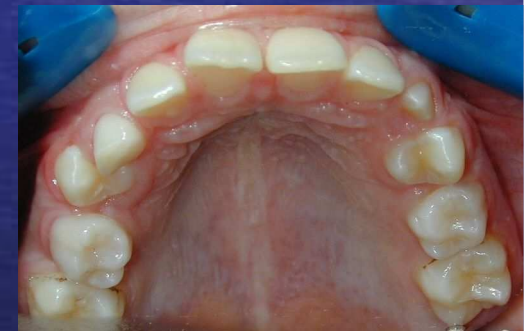
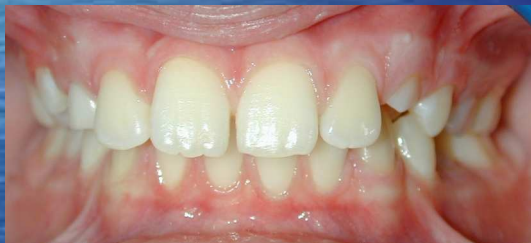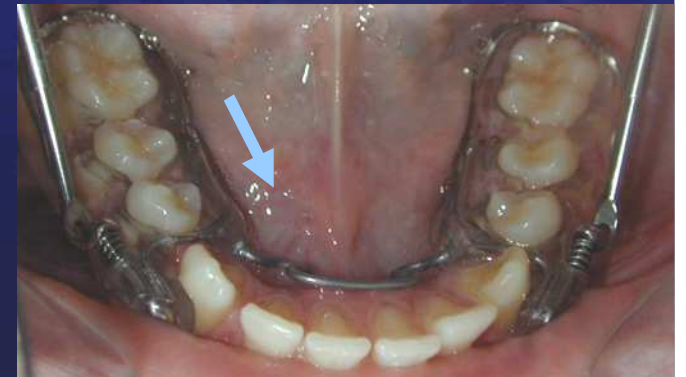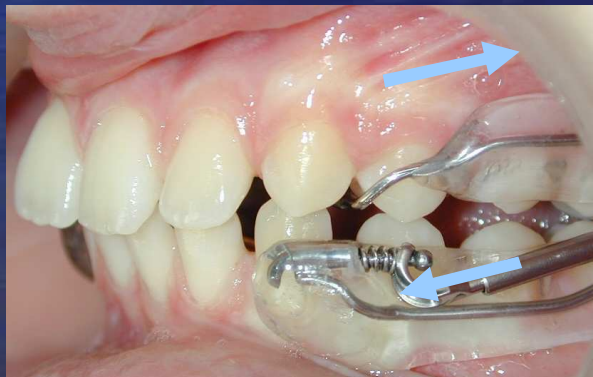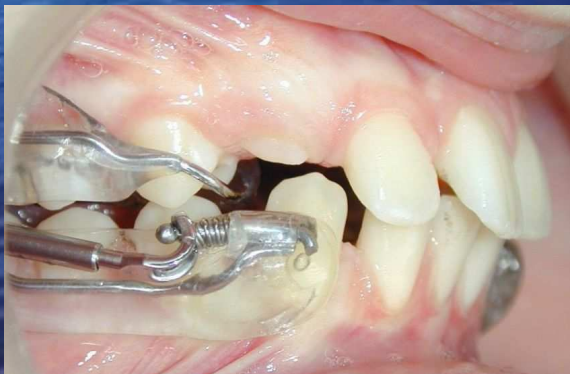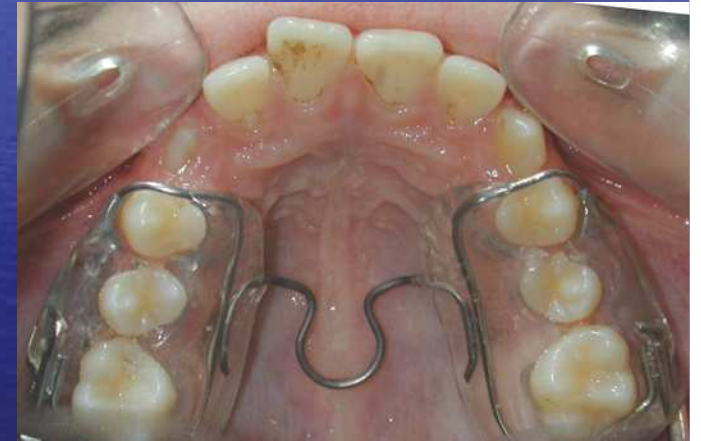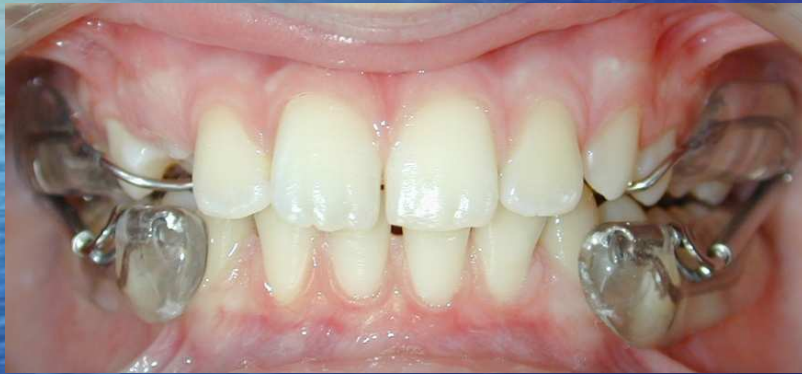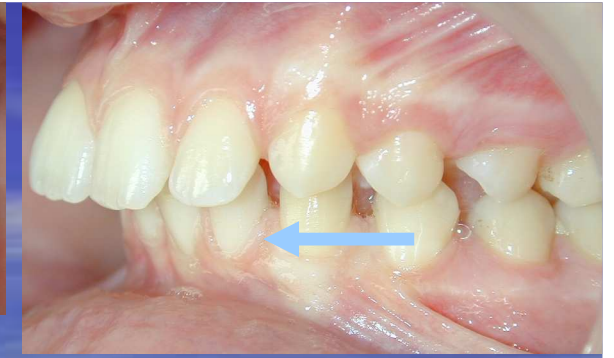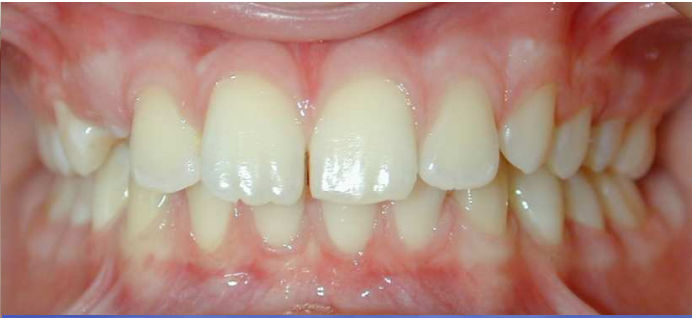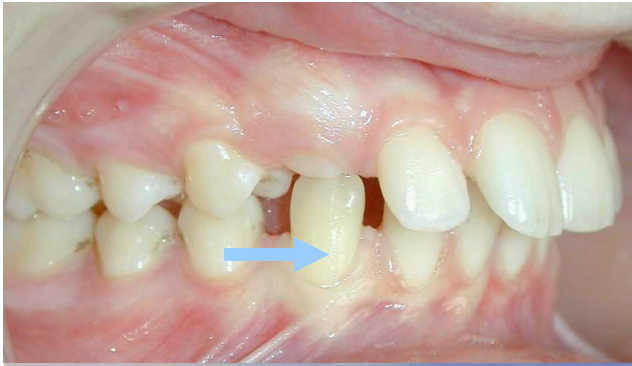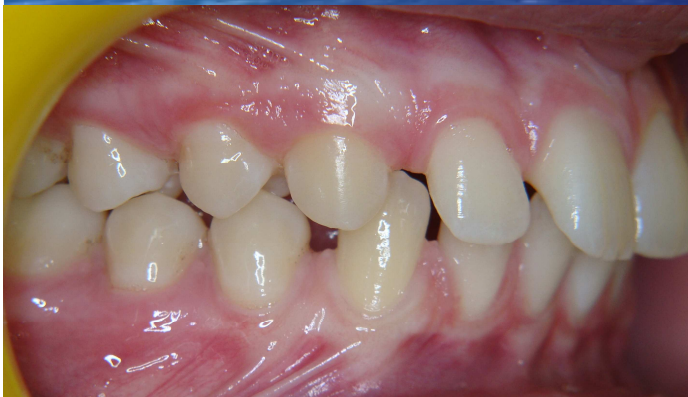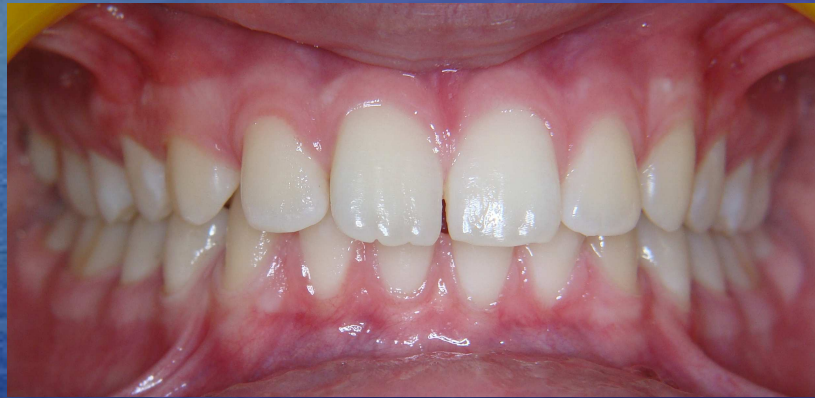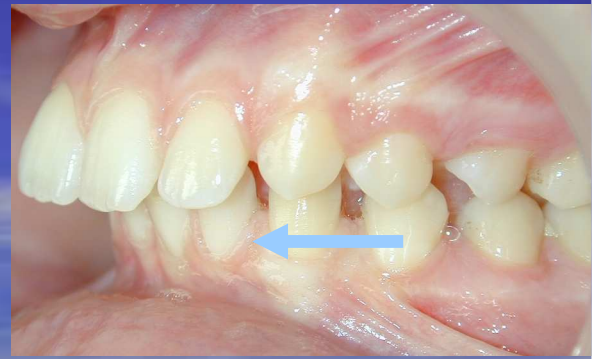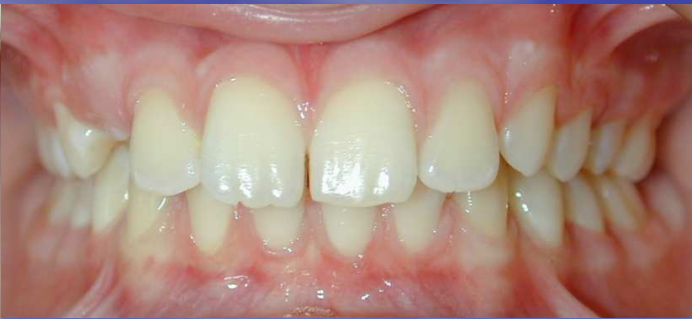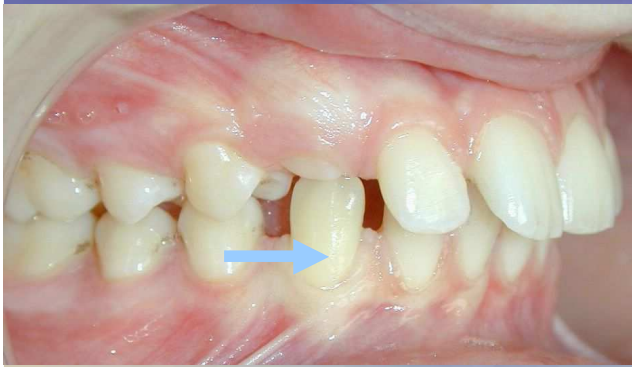Fin 1° phase



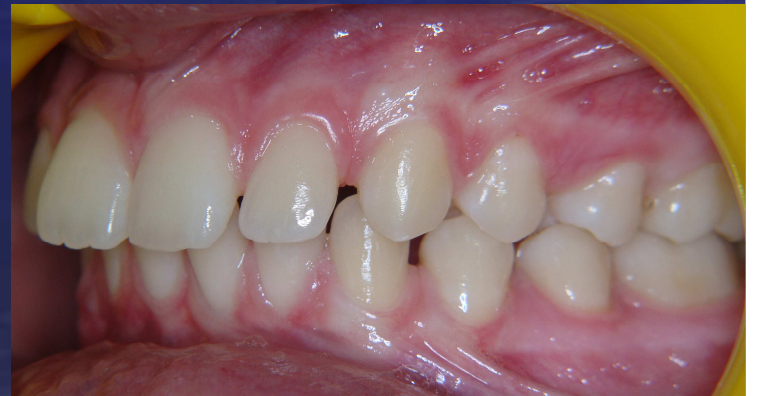13 ans (09/2008)

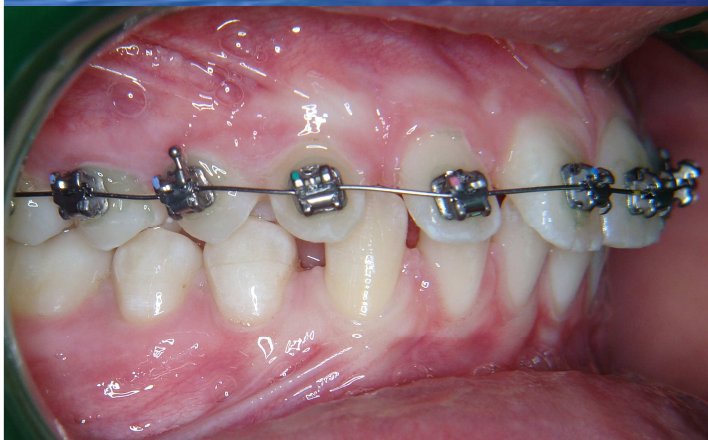
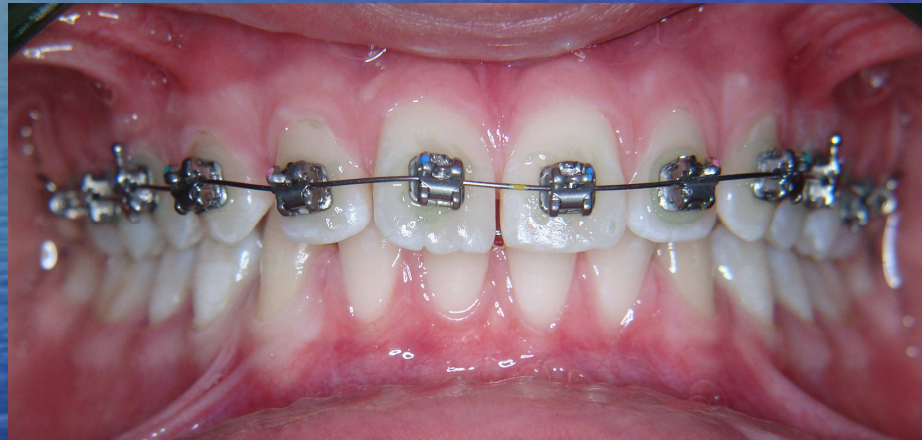
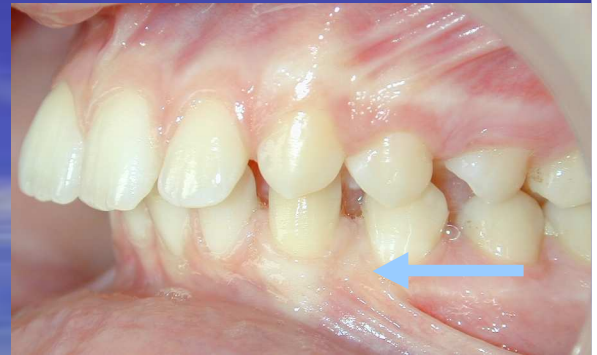
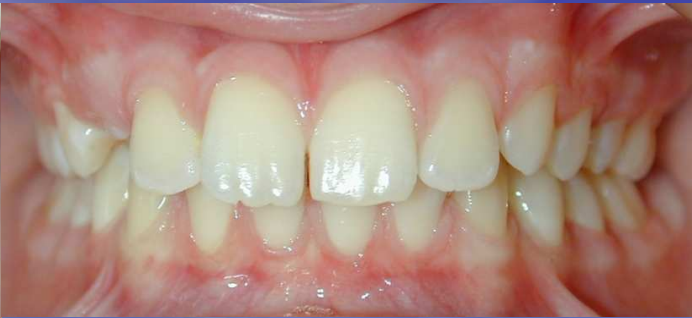
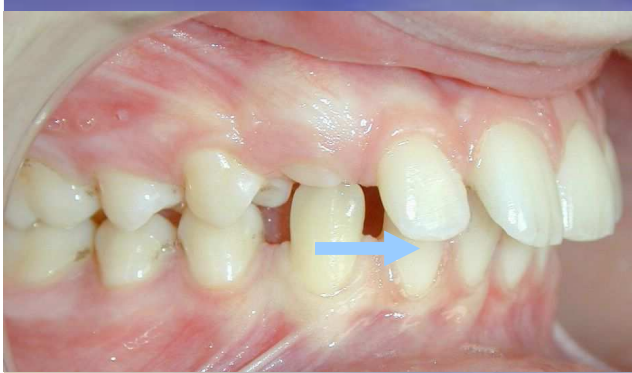
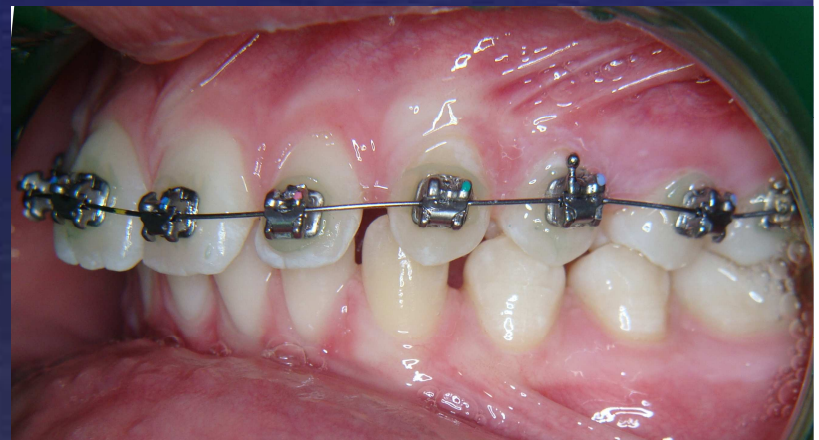


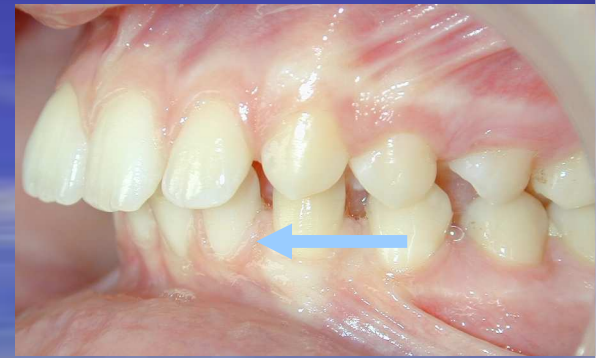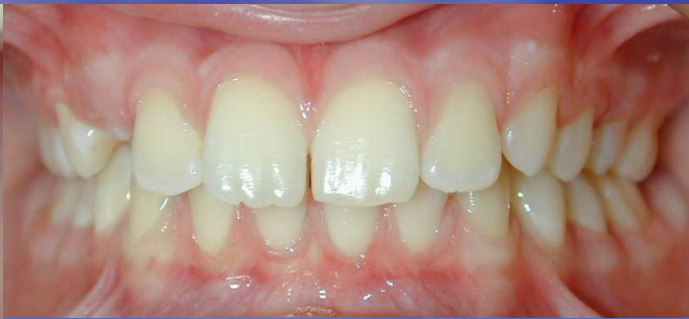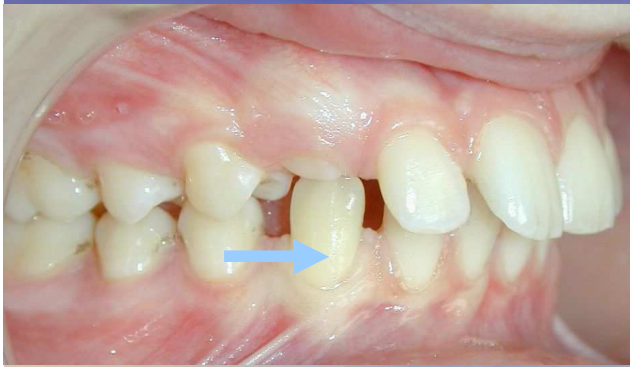PUL + 10 M



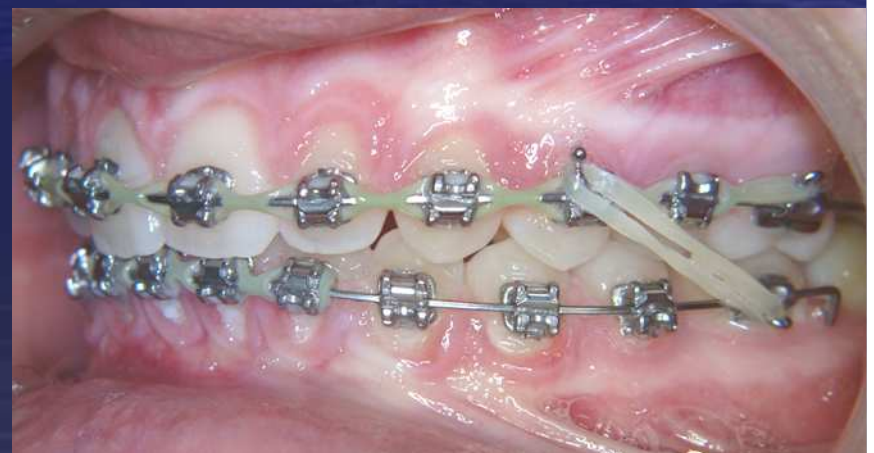
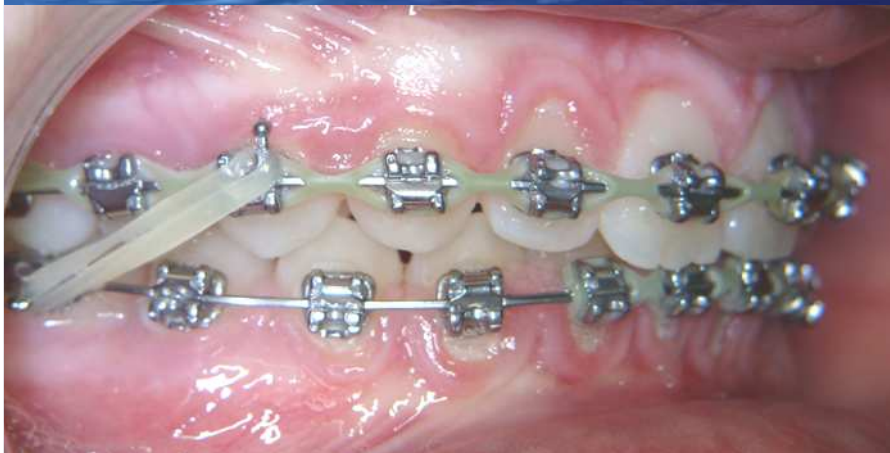
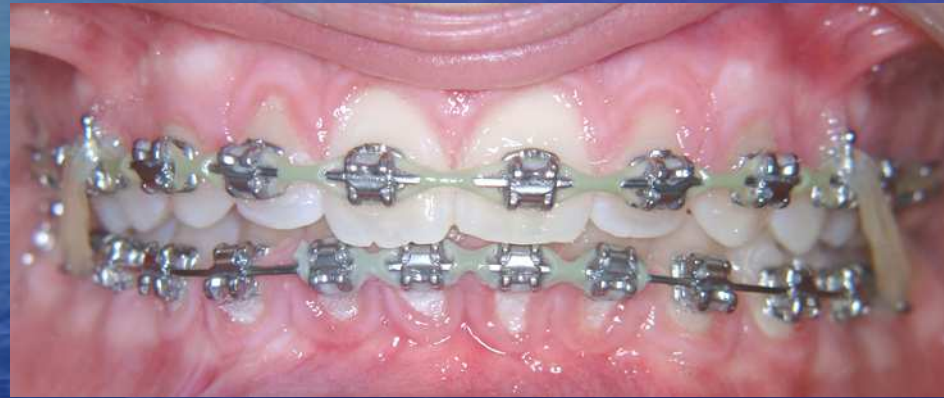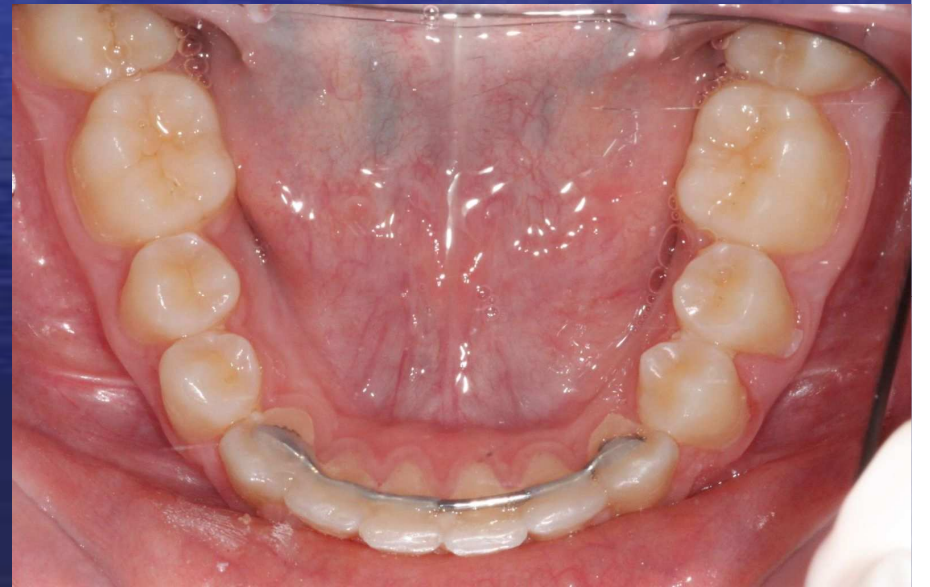
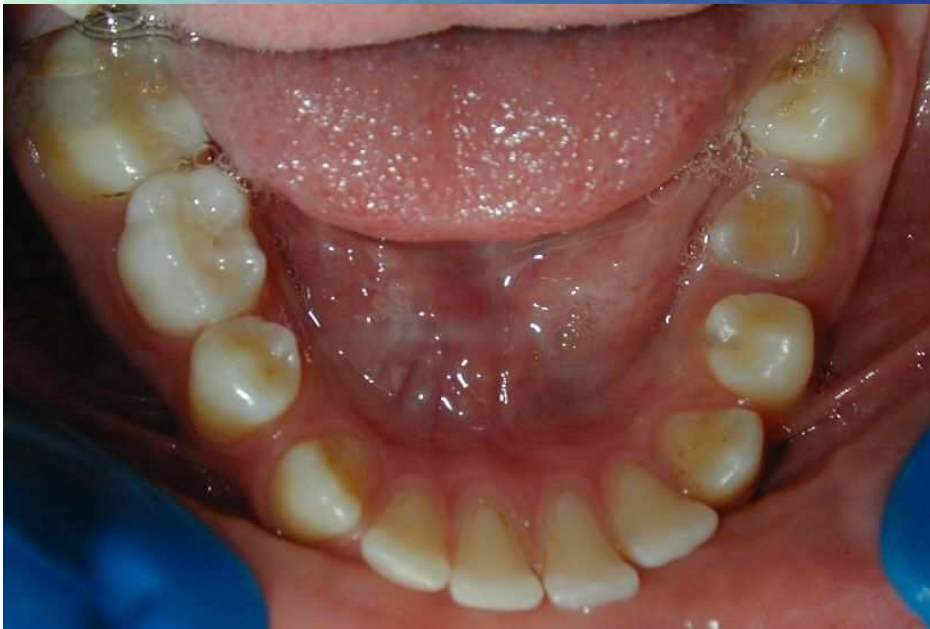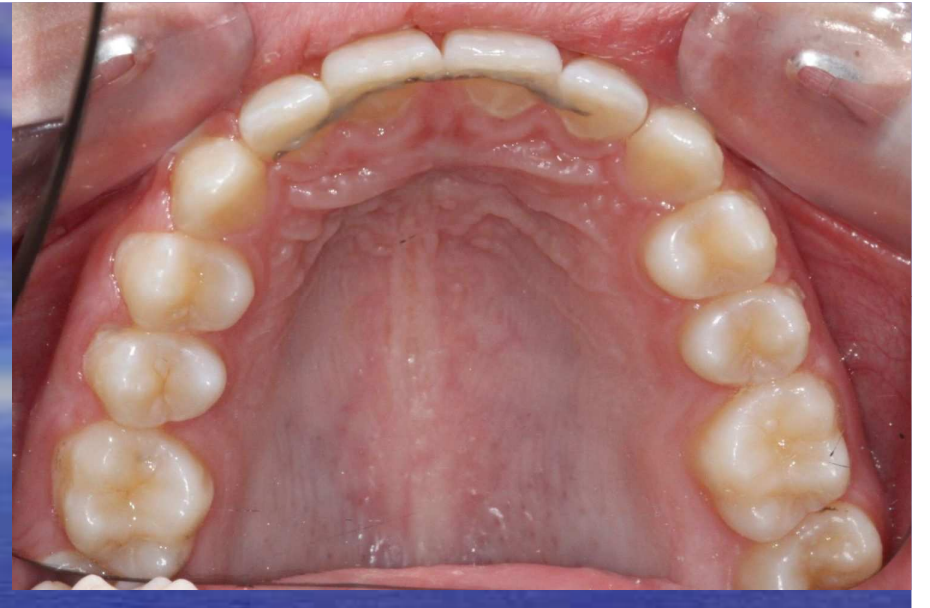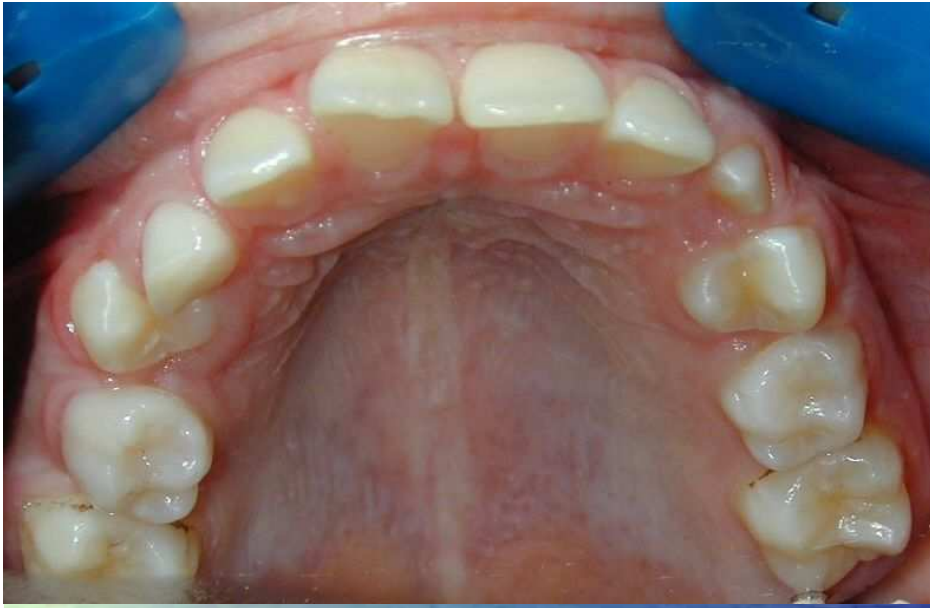08/2009

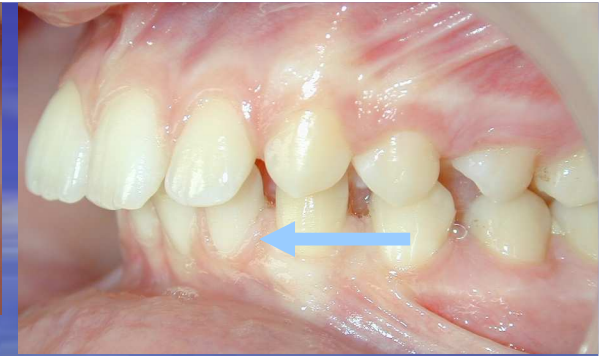
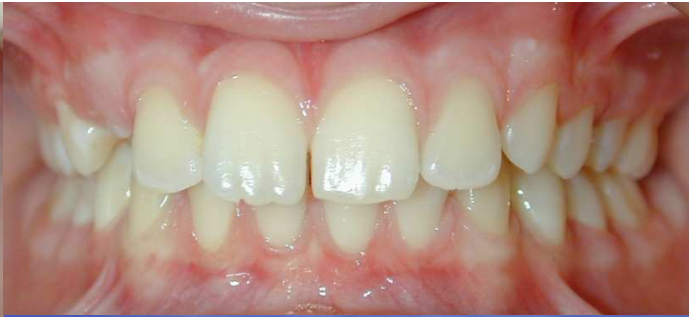
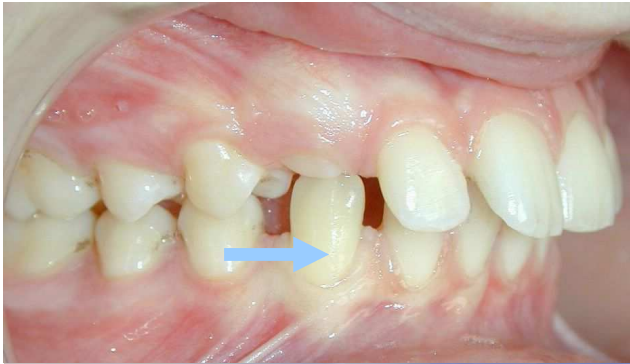

Fixe : 14 M



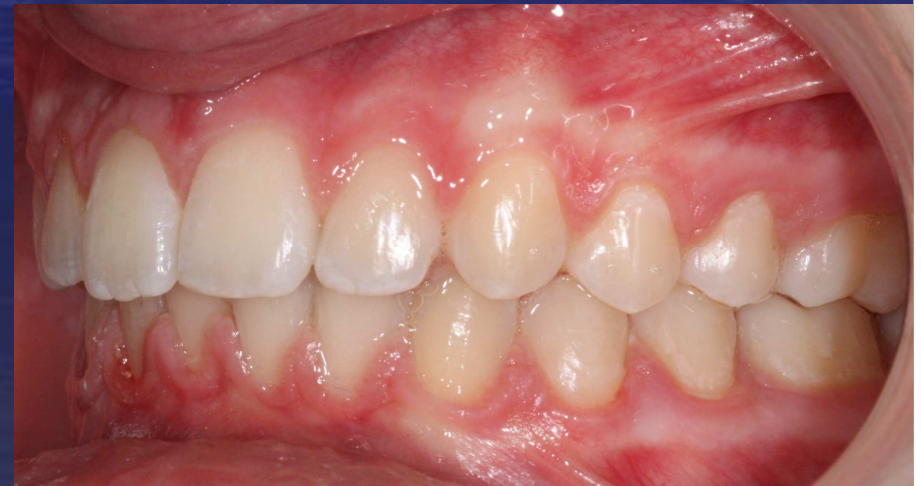
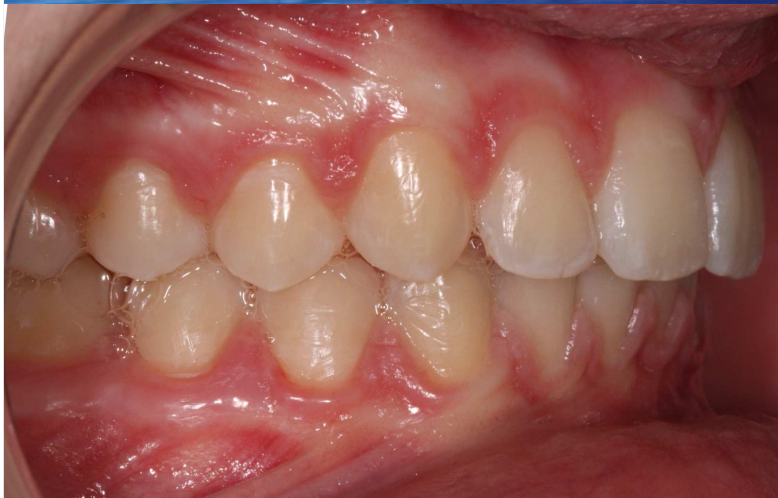
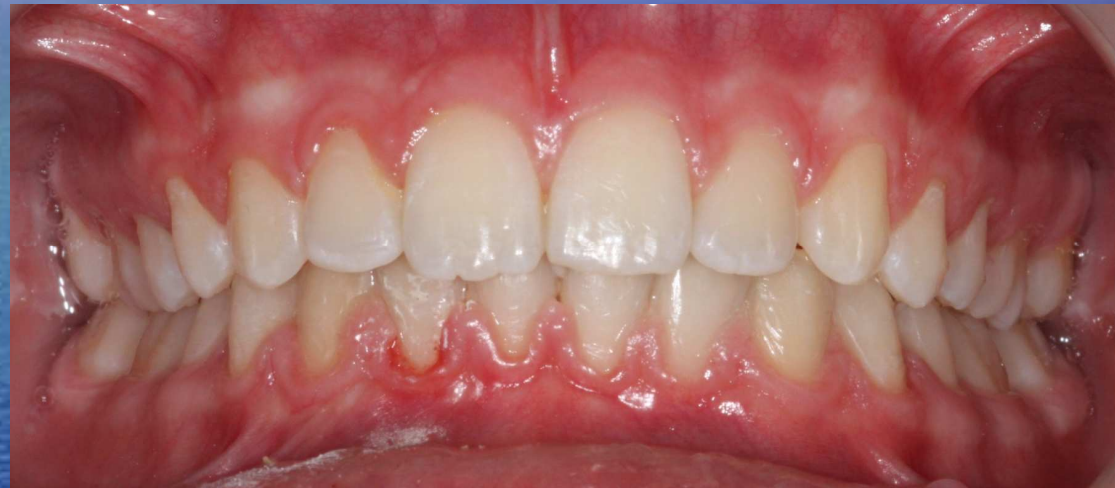

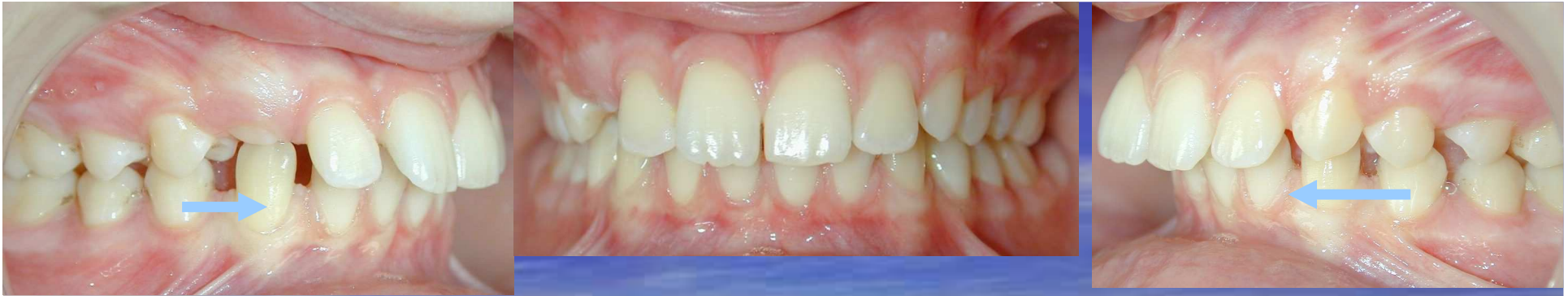PUL 12 M

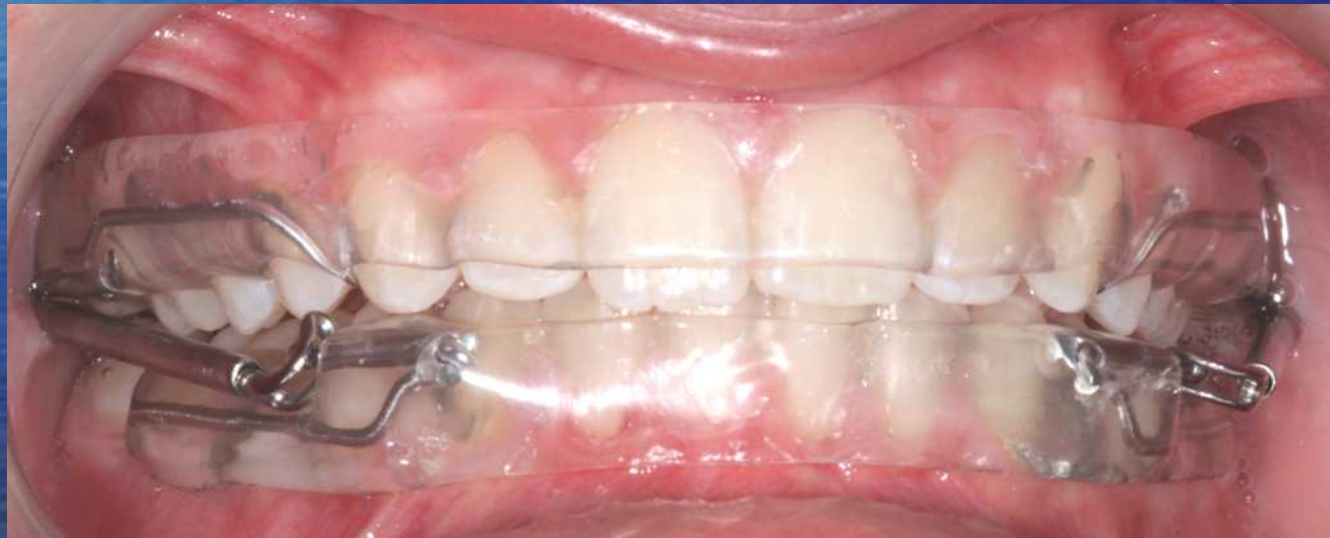PUL TMA 10 M

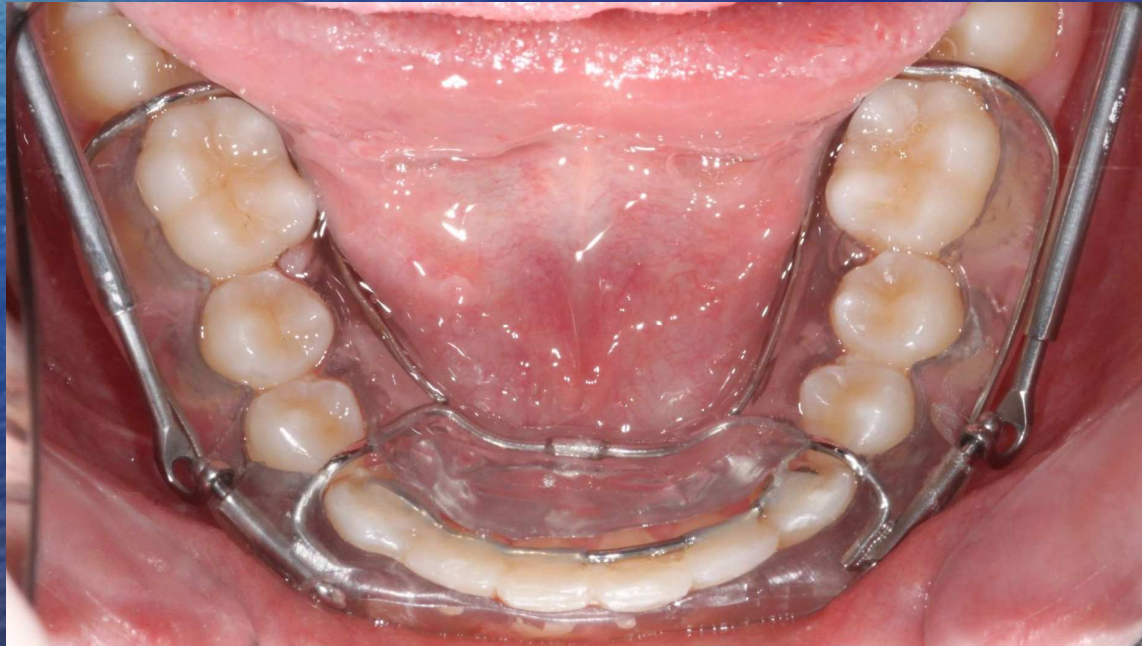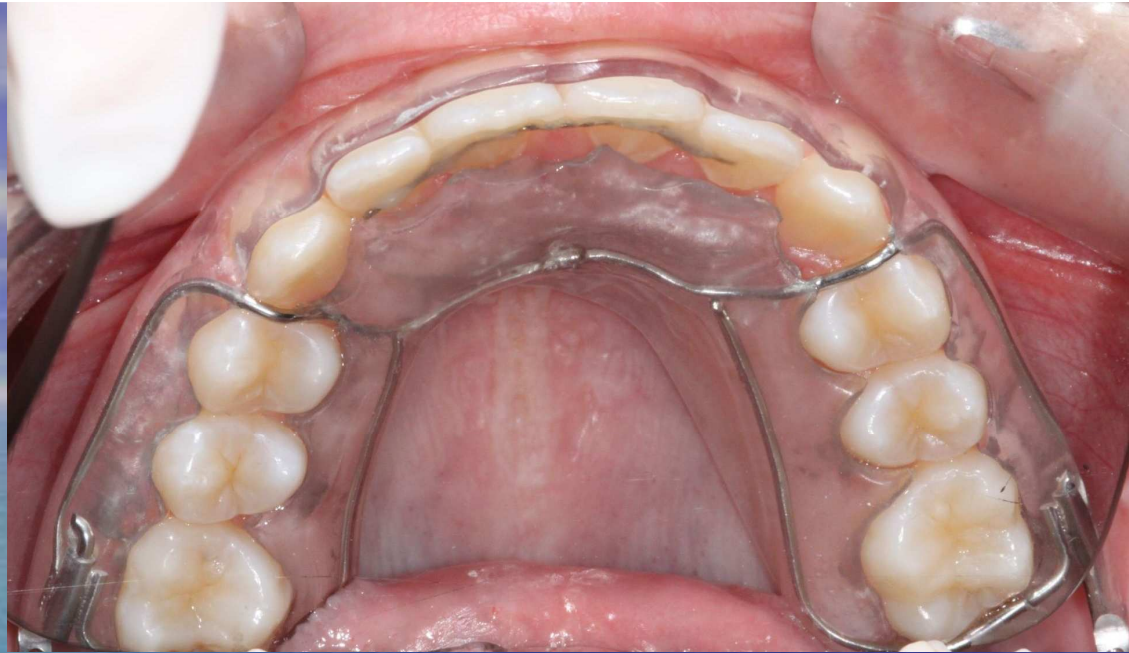
FIXE 14 M

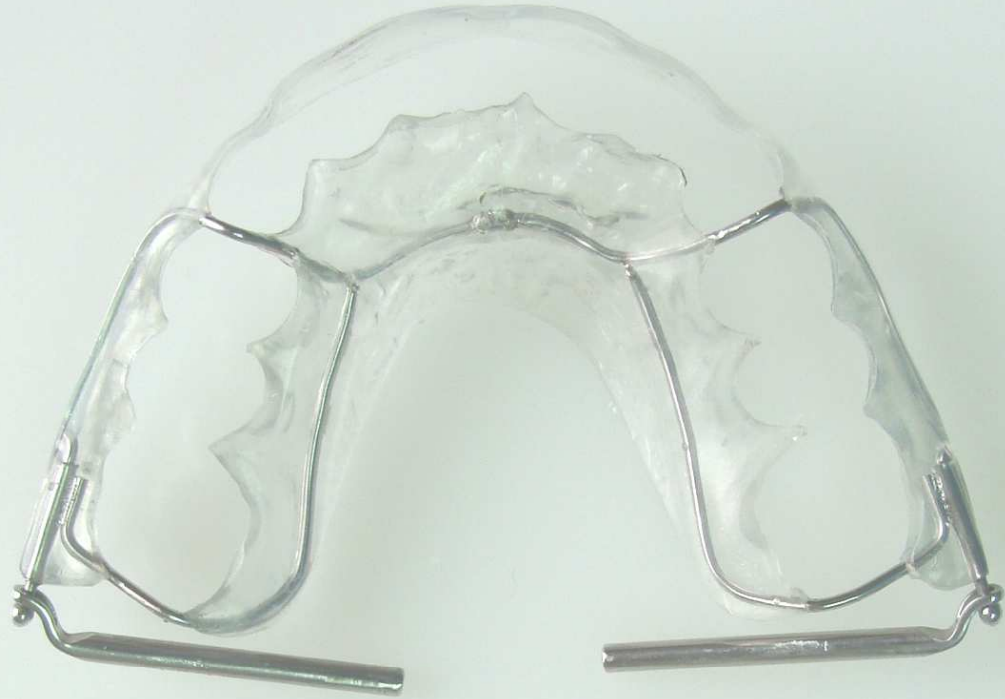

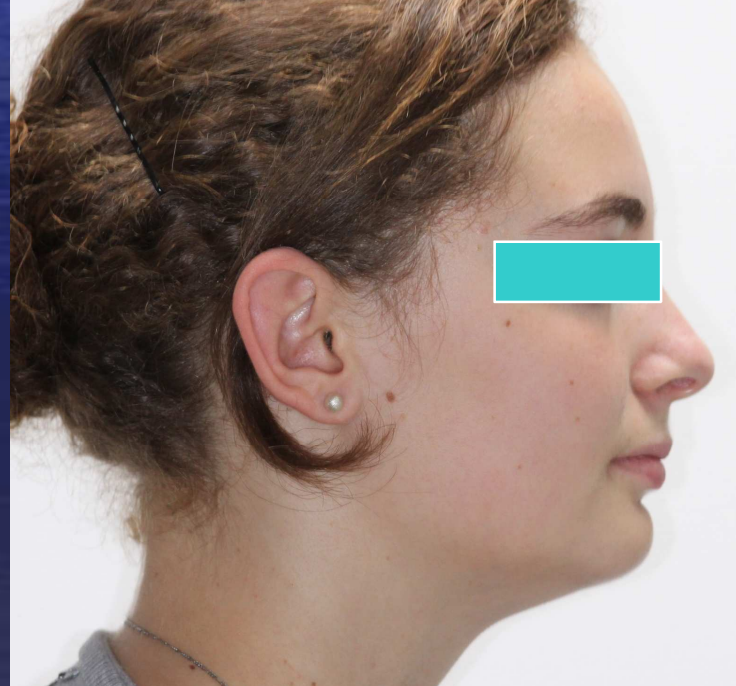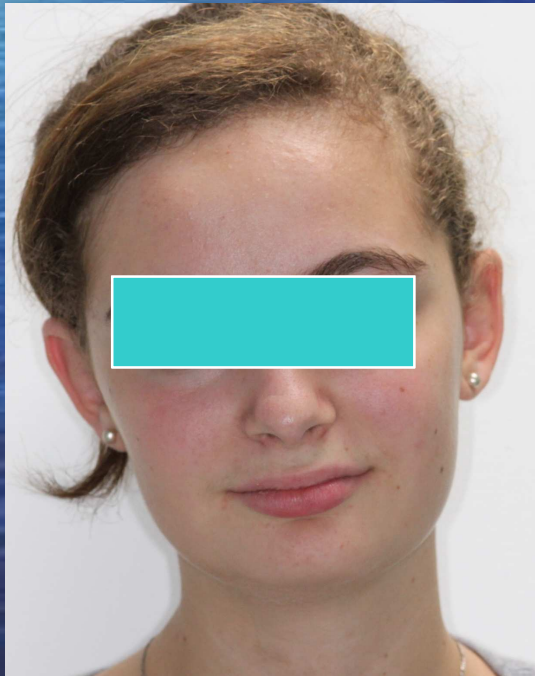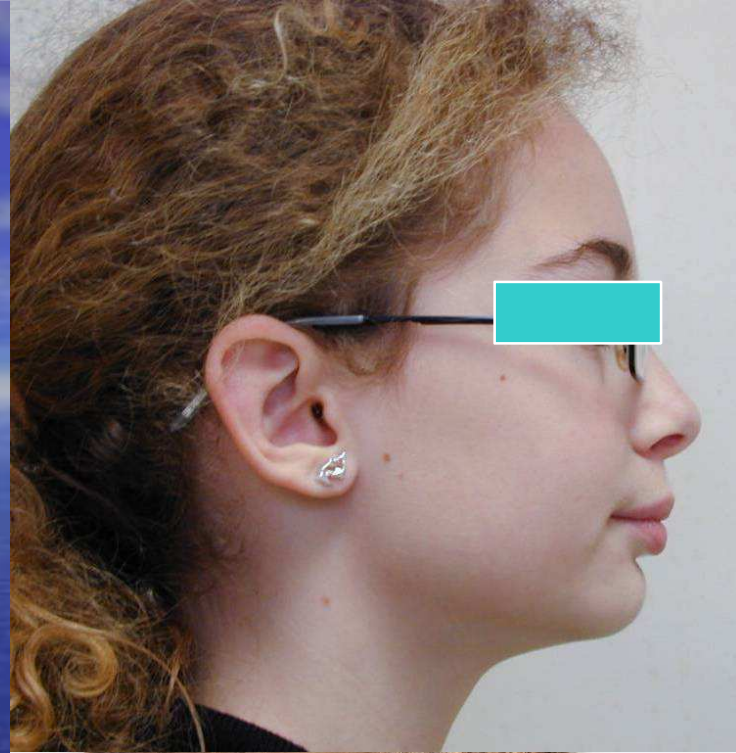



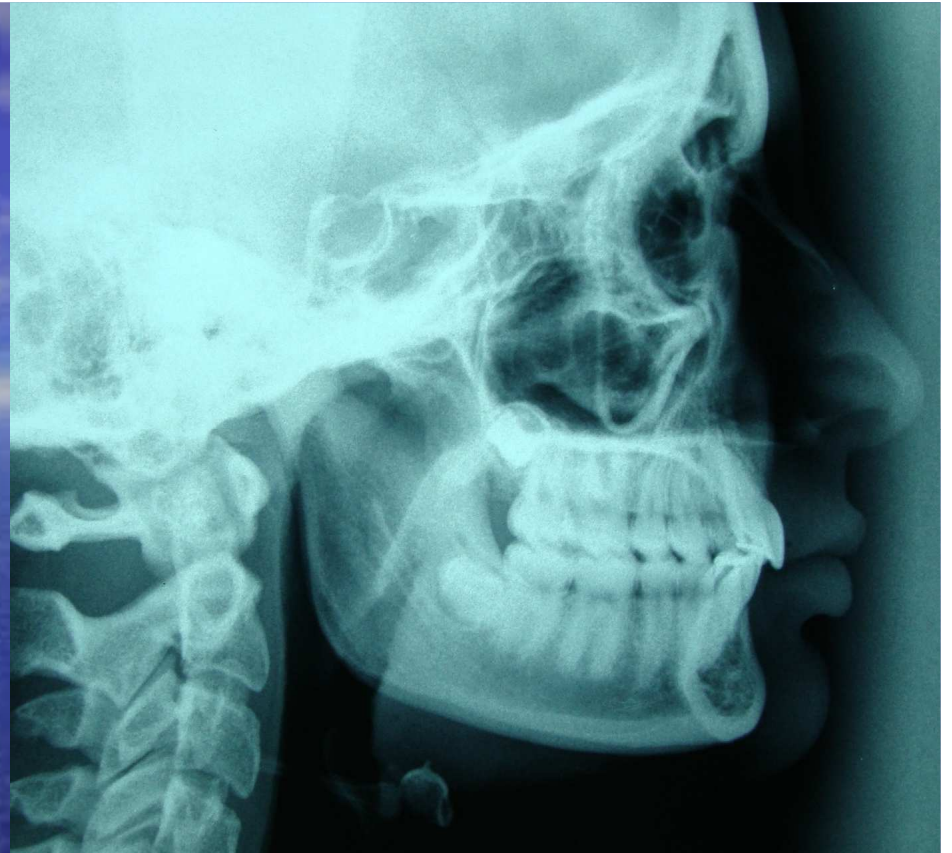
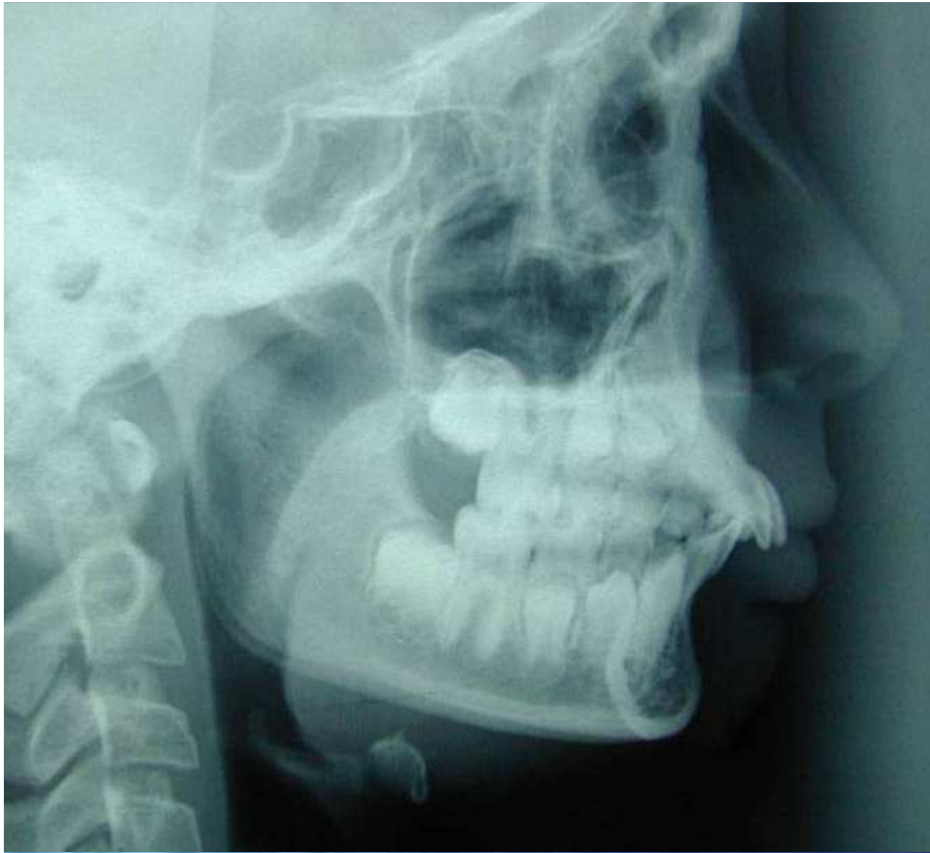Contention 4D

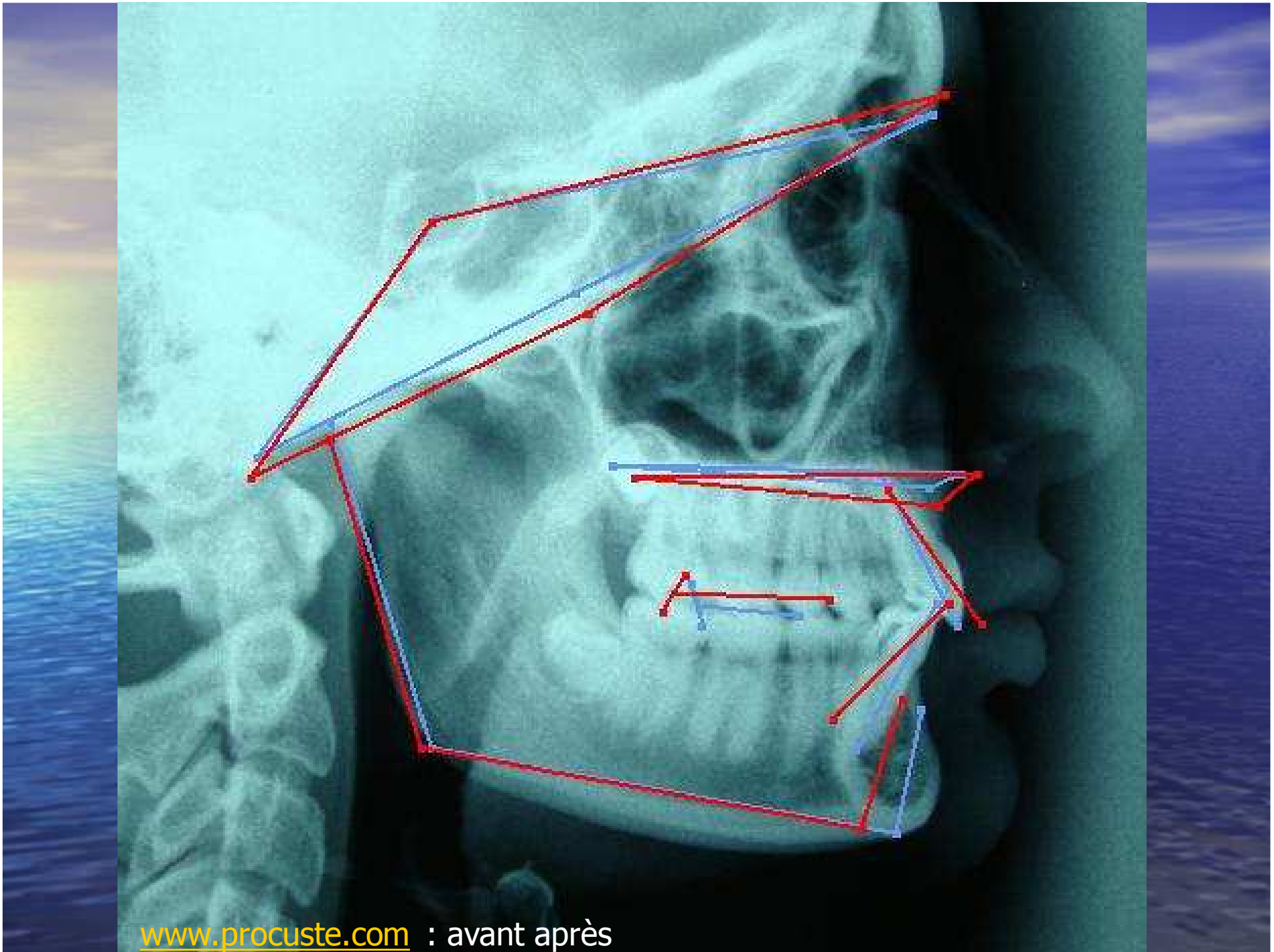












www.procuste.com : avant après